

*FLIR ONE smartphone infrared camera*

**Pre-, Intra- and Postoperative Use of the FLIR ONE Smartphone Infrared  
Camera in Perforator Flap Surgery**

Sven Weum M.D. Ph.D.<sup>1,2</sup>, Alexander Lott M.D.<sup>1,2</sup>, Louis de Weerd M.D. Ph.D.<sup>1,3</sup>

Corresponding Author:

Assoc. Professor Sven Weum M.D. Ph.D.<sup>1,2</sup>

<sup>1</sup>Medical Imaging Research Group

Department of Clinical Medicine

UiT The Arctic University of Norway

9037 Tromsø

Norway

<sup>2</sup>Department of Radiology

University Hospital of North Norway

9038 Tromsø

Norway

<sup>3</sup>Department of Plastic Surgery

University Hospital of North Norway

9038 Tromsø

Norway

Financial Disclosure

None of the authors has a financial interest in any of the products, devices, or drugs mentioned in this manuscript.

To the Editor

We read with interest the article by Hardwicke et al. entitled *Detection of Perforators Using Smartphone Thermal Imaging* (1). Since Itoh and Arai published their first English article on the use of thermography in perforator mapping (2), a number of articles have followed. This is nicely referenced in the book *Imaging for Plastic Surgery* (3). Over the last decade we have routinely used thermal imaging in perforator flap surgery. In addition to systematic comparison with intraoperative findings, we have evaluated thermal imaging in conjunction with ultrasound Doppler, computed tomography and indocyanine green fluorescence angiography (4, 5).

Hardwicke et al. used static thermal imaging. In our experience perforator mapping is most reliably performed with *dynamic infrared thermography* (DIRT). Following a mild cold challenge, rewarming of the skin proceeds via perforators. After cooling, perforators compete with each other in skin rewarming. By analyzing the rate and pattern of rewarming at the hotspots, a suitable perforator can be reliably selected (see Video, Supplemental Digital Content 1). First appearing hotspots are always associated with arterial Doppler signal and related to clearly visible perforators on CT angiography. Hotspots emerging simultaneously can be differentiated by the size of the rewarmed area at the

hotspot, this difference is difficult to visualize with static thermography (Figure 1 and Figure, Supplemental Digital Content 2).

We have documented that intraoperative DIRT can confirm that perforator dissection has been uneventful before flap transfer. Evaluation of the anastomosis is easily performed with DIRT and one can simply differentiate between arterial and venous perfusion problems (4) (see Figure, Supplemental Digital Content 3).

Following flap inset, DIRT can be used to confirm adequate perfusion of the flap. Hardwicke et al. used static thermography to differentiate between well-perfused and inadequately perfused areas of the flap. We argue that this is inappropriate. Our DIRT study on perfusion dynamics of DIEP and SIEA flaps during the first postoperative week clearly demonstrated that perfusion of these flaps is a dynamic process. There is a stepwise progression of perfusion that proceeds faster at the level of the subdermal plexus than at the subcutaneous layer. Thermography during the first postoperative week reveals the appearance of hotspots that were not visible intraoperatively. Resection based on intraoperative thermography may therefore result in discarding of viable tissue.

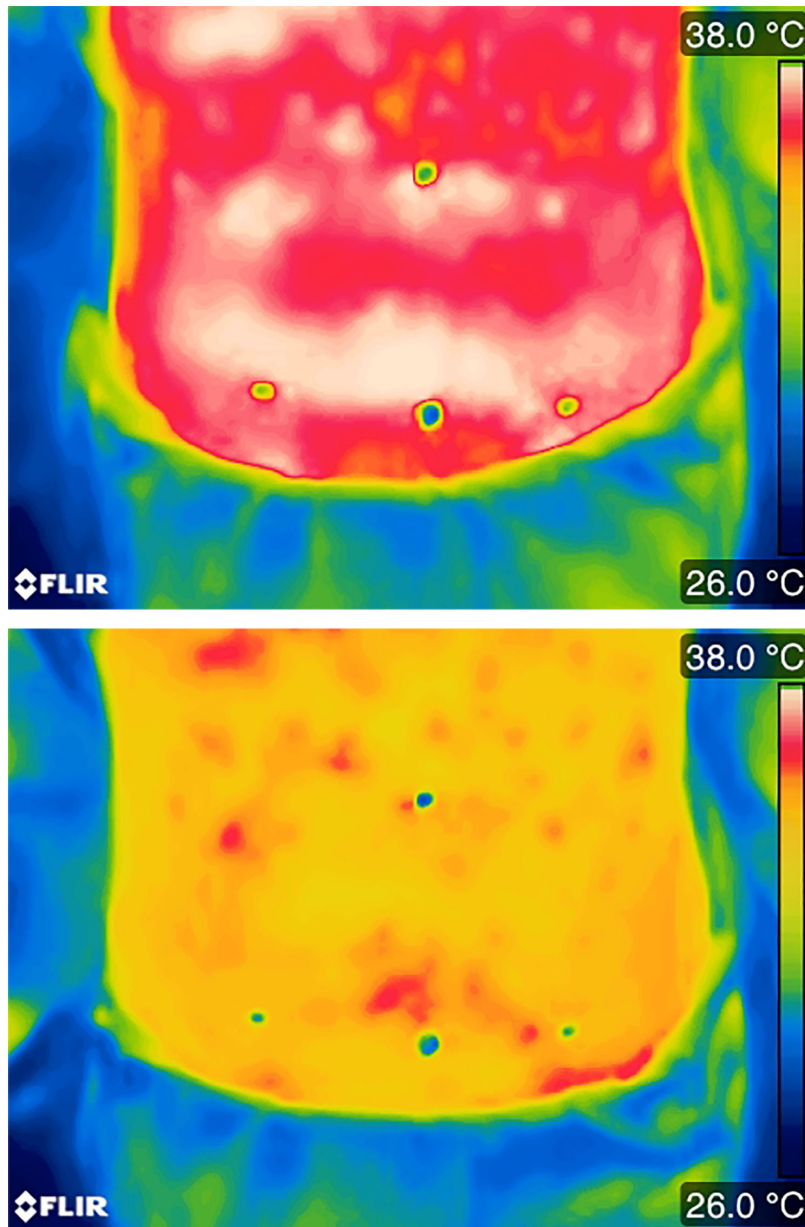
Curran and colleagues have concluded that the FLIR ONE does not appear suitable for collecting absolute temperature data (6). However, in perforator mapping only relative temperature differences are used. DIRT can increase the reliability of FLIR ONE for perfusion imaging in the pre-, intra- and postoperative phases of perforator flap surgery.

*FLIR ONE smartphone infrared camera*

We congratulate Hardwicke et al. for bringing attention to the use of inexpensive smartphone infrared cameras in perforator flap surgery. The FLIR ONE has considerable technical limitations. We would recommend using cameras with higher resolution for diagnostics, evaluation of treatment and research purposes. Nevertheless, smartphone infrared cameras may have interesting potential as an alternative to expensive thermal cameras in certain clinical situations. More research is necessary to evaluate their utility in clinical and research practice.

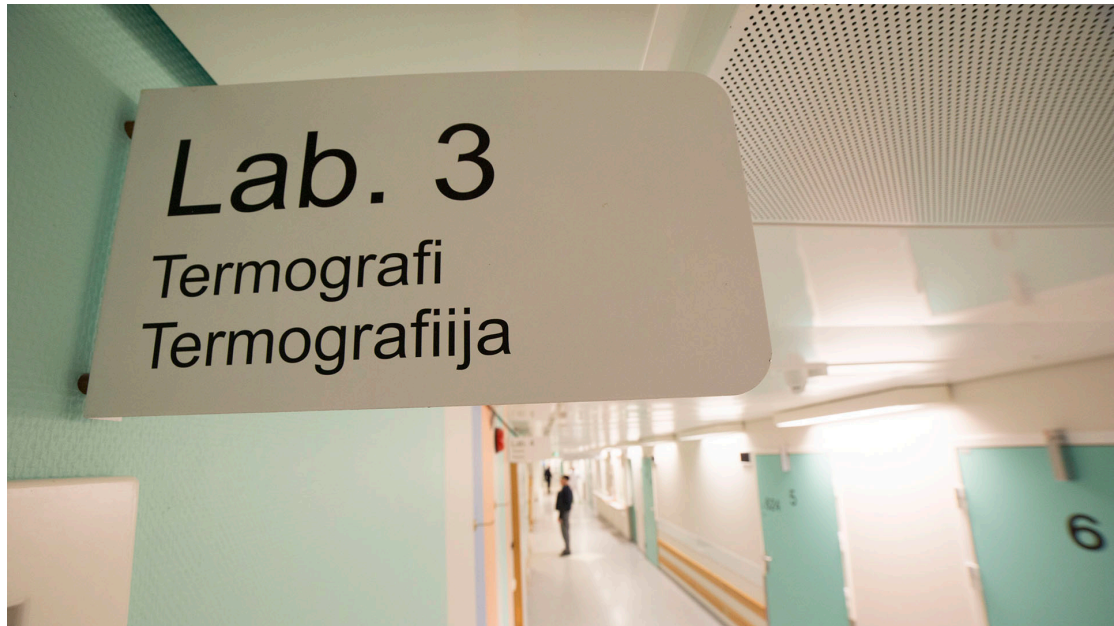## **REFERENCES**

1. Hardwicke, J. T., Osmani, O., Skillman, J. M. Detection of Perforators Using Smartphone Thermal Imaging. *Plast Reconstr Surg* 2016;137:39-41.
2. Itoh, Y., Arai, K. The deep inferior epigastric artery free skin flap: anatomic study and clinical application. *Plast Reconstr Surg* 1993;91:853-863; discussion 864.
3. Niumsawatt, V., Rozen, W. M., Whitaker, I. S. Digital Thermographic Photography for Preoperative Perforator Mapping. In L. Saba, W. M. Rozen, A. Alonso-Burgos, D. Ribuffo eds., *Imaging for Plastic Surgery*. Boca Raton (FL): CRC Press; 2015:129-140.
4. de Weerd, L., Mercer, J. B., Weum, S. Dynamic infrared thermography. *Clin Plast Surg* 2011;38:277-292.
5. Miland, A. O., de Weerd, L., Weum, S., Mercer, J. B. Visualising skin perfusion in isolated human abdominal skin flaps using dynamic infrared thermography and indocyanine green fluorescence video angiography. *Eur J Plast Surg* 2008;31:235-242.
6. Curran, A., Klein, M., Hepokoski, M., Packard, C. Improving the accuracy of infrared measurements of skin temperature. *Extreme Physiology & Medicine* 2015;4:1.



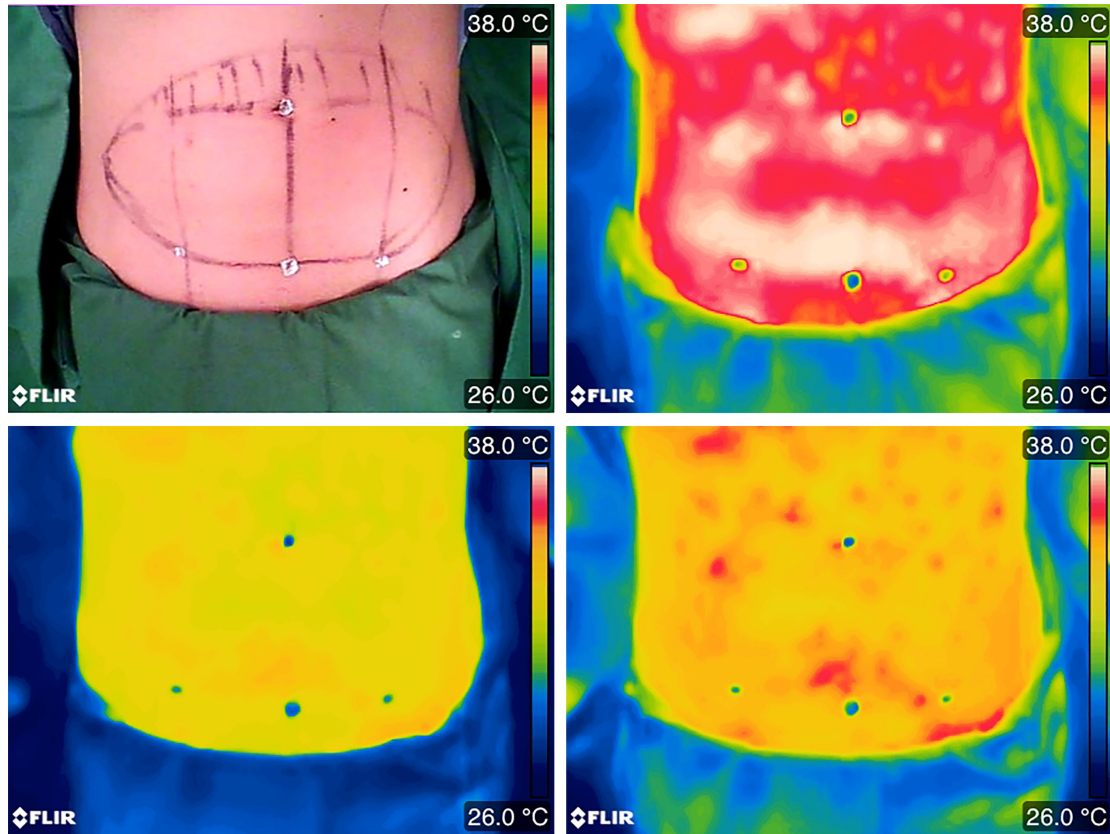
**Figure 1**

Static thermal imaging with FLIR ONE after acclimatization but no cooling (upper figure) and DIRT recorded with FLIR ONE in the preoperative phase (lower figure). After 2 minutes cooling with a desktop fan, recording of the rewarming phase visualizes the difference between the bright hotspot on the right and left side. In contrast to Hardwicke et al., we prefer using a rainbow palette to highlight small differences in temperature.



**Video, Supplemental Digital Content 1**


Dynamic infrared thermography in preoperative perforator mapping



**Figure, Supplemental Digital Content 2**

DIRT recorded with FLIR ONE in the preoperative phase. After 2 minutes cooling with a desktop fan, recording of the rewarming phase visualizes the difference between the bright hotspot on the right and left side. With static thermal imaging (upper right figure) this difference would be more difficult to visualize, even after a period of acclimatization.





**Figure, Supplemental Digital Content 3**

FLIR ONE images visualizing the appearance of hotspots located over the selected perforator (marked with a cross) after opening of the anastomosis. Within three minutes the number and brightness of hotspots increase.