




Contents lists available at ScienceDirect

JPRAS Open

journal homepage: <http://www.journals.elsevier.com/jpras-open>

## Case report

## Combining autologous ventral hernia repair using component separation with DIEP breast reconstruction

Louis de Weerd<sup>a, d, \*</sup>, Solveig Nergård<sup>a</sup>, Rolv-Ole Lindsetmo<sup>b, e</sup>, Sven Weum<sup>c, d</sup><sup>a</sup> Department of Plastic Surgery and Hand Surgery, University Hospital of North Norway, Tromsø, Norway<sup>b</sup> Department of Gastroenterologic Surgery, University Hospital of North Norway, Tromsø, Norway<sup>c</sup> Department of Radiology, University Hospital of North Norway, Tromsø, Norway<sup>d</sup> Medical Imaging Research Group, Department of Clinical Medicine, UiT The Arctic University of Norway, Tromsø, Norway<sup>e</sup> Gastrosurgical Research Group, Department of Clinical Medicine, UiT The Arctic University of Norway, Tromsø, Norway

## ARTICLE INFO

## Article history:

Received 13 July 2015

Accepted 29 July 2015

Available online 2 September 2015

## Keywords:

Free flap

Breast reconstruction

Abdominal wall reconstruction

Midline hernia

Incisional hernia

## ABSTRACT

Concern about flap viability and abdominal wall integrity would normally exclude a patient with a large ventral midline hernia from having a breast reconstruction with a deep inferior epigastric perforator (DIEP) flap. Ventral hernia repair using the abdominoplasty approach has been reported before. The abdominoplasty flap would normally be discarded. This article presents a unique case of a patient with a large incisional midline hernia who had a combined procedure of autologous hernia repair using component separation technique and DIEP breast reconstruction. The indications for DIEP breast reconstruction are therewith expanded. © 2015 The Authors. Published by Elsevier Ltd on behalf of British Association of Plastic, Reconstructive and Aesthetic Surgeons. This is an open access article under the CC BY-NC-ND license (<http://creativecommons.org/licenses/by-nc-nd/4.0/>).

## Introduction

The lower abdomen is unmatched as donor site for breast reconstruction as it provides adequate tissue volume with a consistency resembling a natural breast. Mehrara et al. reported an increased risk for both donor site and flap related complications in patients with abdominal scars.<sup>1</sup> This article

\* Corresponding author. Department of Plastic Surgery and Hand Surgery, University Hospital of North Norway, 9038 Tromsø, Norway. Tel.: +47 91507766; fax: +47 77627164.

E-mail address: [louis.deweerd@unn.no](mailto:louis.deweerd@unn.no) (Professor L. de Weerd).

<http://dx.doi.org/10.1016/j.jpra.2015.07.005>

2352-5878/© 2015 The Authors. Published by Elsevier Ltd on behalf of British Association of Plastic, Reconstructive and Aesthetic Surgeons. This is an open access article under the CC BY-NC-ND license (<http://creativecommons.org/licenses/by-nc-nd/4.0/>).

presents a unique case of a patient with a large incisional midline hernia who had DIEP breast reconstruction and hernia repair using component separation technique as a combined procedure.

### Case illustration

A 54-year-old woman was referred for bilateral breast reconstruction. Left-sided mastectomy had been performed for breast cancer followed by adjuvant chemoradiotherapy. After diagnosing BRCA-2 gene mutation prophylactic mastectomy combined with implant breast reconstruction had been performed on the right side. The implant was removed due to infection. Prophylactic oophorectomy was done on a later date using a midline approach; she had a history of four caesarean sections, all through a midline incision. She developed a large ventral midline hernia (Figure 1). CT scanning revealed an abdominal wall defect of 10 cm transversely and 15 cm vertically. CT angiography visualized only one suitable perforator on the right and only a small superficial circumflex iliac artery (SCIA) on the left side. The patient consented to hernia repair combined with autologous and/or implant breast reconstruction in one session.

### Surgical procedure

In general anesthesia, the skin and subcutaneous tissue were dissected from the hernia sac. Based on a single lateral row perforator, a hemi-DIEP flap of 305 grams was elevated on the right side. On the left side a flap of 285 grams based on a small caliber SCIA was elevated (Figure 2). The DIEP flap was successfully anastomosed to the left internal mammary vessels and a breast was molded. The anastomosis of the SCIA flap to the right internal mammary vessels was repeatedly complicated by arterial thrombosis. Finally, the right breast was reconstructed using an expander implant. The hernia sac was resected. The open component separation technique as described by Ramirez et al. but without incision of the posterior rectus sheath was used for hernia repair.<sup>2</sup> Bilaterally, the aponeurosis of the external oblique muscle was vertically divided 1 cm lateral to the semilunar line from the inguinal region to the costal margin. The external oblique muscle was separated from the internal oblique muscle in an avascular plane. The two innervated composite complexes of rectus abdominis, internal oblique and transversus abdominis muscles were advanced medially and sutured together at the midline using a

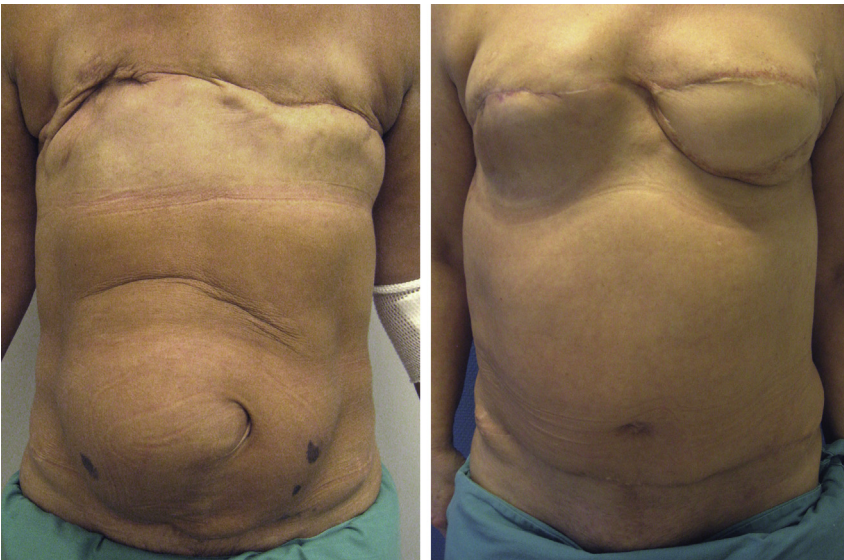
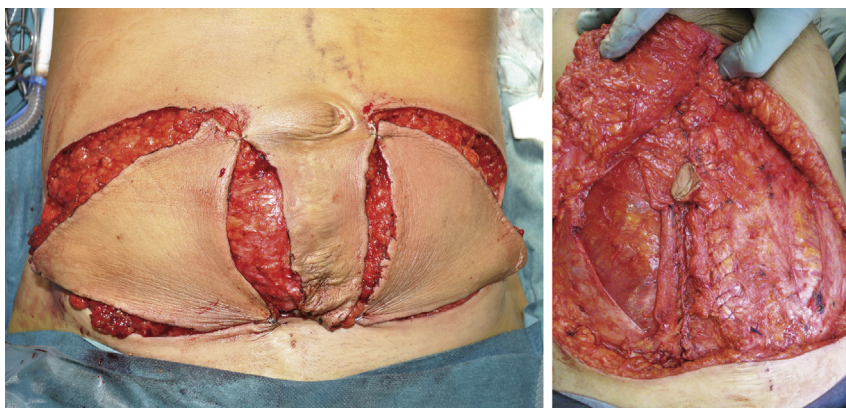


Figure 1. Preoperative view (left), postoperative view (right).



**Figure 2.** Intraoperative view, both flaps are dissected from the hernia sac which is covered at the midline with skin (left). Hernia repair with component separation technique (right).

single layer monofilament suture (Figure 2). No mesh was used in the hernia repair. The remaining wound was closed as in an abdominoplasty. The postoperative course was uneventful. Six months later the expander was exchanged for an anatomically shaped implant (Figure 1).

## Discussion

Due to concerns about flap viability as well as abdominal wall integrity, patients with abdominal scars may be denied breast reconstruction with a DIEP flap.<sup>1,3</sup> Our patient had four caesarean sections all through a midline approach and developed a large incisional ventral hernia after oophorectomy through a midline incision. Incisional hernia represents one of the most frequent complications after abdominal surgery, with a reported incidence rate of 11%–20%.<sup>4</sup>

In 1990 Ramirez et al. described the concept of open component separation technique for closure of abdominal wall defects.<sup>2</sup> The technique allows for autologous and dynamic reconstruction of the abdominal wall in patients with large ventral midline hernias. The hernia repair may be performed using an abdominoplasty approach.<sup>5,6</sup> This approach provides an excellent exposure of both the abdominal wall as well as the hernia and isolates the skin incision from the hernia repair. Normally, the excess of skin and subcutaneous tissue would be discarded as in an abdominoplasty. We planned to harvest this tissue as a free perforator flap for autologous breast reconstruction and to combine that procedure with the hernia repair.

The presence of abdominal scars and incisional ventral hernia in our patient made preoperative perforator mapping necessary as previous abdominal surgery may change the vascular anatomy. The findings of CT angiography corresponded well with the intraoperative findings with only one perforator suitable for a DIEP flap on the right side and with only a small caliber SCIA and no perforators on the left side. Priority was given to autologous breast reconstruction on the left side because of previous irradiation therapy at this side. The DIEP flap from the right side was successfully used for reconstruction of the left breast. The SCIA flap could not be used in our patient.

The main objectives of abdominal wall reconstruction are to provide stable soft tissue coverage and structural support with minimal morbidity.<sup>2</sup> Good results have been reported using the component separation technique for midline hernia repairs.<sup>2,5</sup> Nevertheless, having used this technique in combination with mesh reinforcement of the hernia repair, Harth and Rozen reported a recurrence rate of 30%.<sup>7</sup> Incisional ventral hernia is not only a complication following abdominal surgery. It has also been reported as a rare donor site complication after DIEP breast reconstruction.<sup>8</sup> During the two years follow-up no signs of hernia recurrence or bulging could be detected in our patient (Figure 1).

We have not found published cases of combined autologous ventral hernia repair using the component separation technique and DIEP breast reconstruction. The approach for DIEP breast

reconstruction provides an excellent exposure for hernia repair with the component separation technique. The existence of the hernia and scar formation after previous surgery can make the harvest of a free perforator flap more demanding. CT allows examining the extent of the abdominal wall defect as well as the structures of the abdominal wall, while CT angiography can provide information on the presence of suitable perforators. With adequate preoperative planning the possibility for a combined procedure of hernia repair and DIEP breast reconstruction can be evaluated. Both component separation technique for hernia repair and DIEP breast reconstruction are well-established surgical techniques. This article illustrates that for selected patients autologous hernia repair with a component separation technique can be combined with DIEP breast reconstruction. In such, the indications for autologous breast reconstruction with a free flap from the lower abdomen are further expanded.

### Conflicts of interest

None declared.

### Ethical approval

Not required.

### Funding

None.

### References

1. Mehrara BJ, Santoro TD, Arcilla E, Watson JP, Shaw WW, Da Lio AL. Complications after microvascular breast reconstructions: experience with 1195 flaps. *Plast Reconstr Surg.* 2006;118:1100–1109.
2. Ramirez OM, Ruas E, Dellon AL. "Components separation" method for closure of abdominal wall defects: an anatomic and clinical study. *Plast Reconstr Surg.* 1990;86:519–526.
3. Parrett BM, Caterson SA, Tobias AM, Lee BT. DIEP flaps in women with abdominal scars: are complication rates affected? *Plast Reconstr Surg.* 2008;121:1527–1531.
4. Nieuwenhuizen J, Eker HH, Timmermans L, et al. A double blind randomized controlled trial comparing primary suture closure with mesh augmented closure to reduce incisional hernia incidence. *BMC Surg.* 2013;13:48. <http://dx.doi.org/10.1186/1471-2482-13-48>.
5. Robertson JD, de la Torre JI, Gardner PM, Grant JH, Fix TJ, Vásquez LO. Abdominoplasty repair for abdominal wall hernias. *Ann Plast Surg.* 2003;51:10–16.
6. Koolen PG, Ibrahim AM, Kim K, et al. Patient selection optimization following combined abdominal procedures: analysis of 4925 patients undergoing panniculectomy/abdominoplasty with or without concurrent hernia repair. *Plast Reconstr Surg.* 2014;134:539e–550e.
7. Harth KC, Rosen MJ. Endoscopic versus open component separation in complex abdominal wall reconstruction. *Am J Surg.* 2010;199:342–347.
8. Man L, Selber JC, Serletti JM. Abdominal wall following free TRAM or DIEP flap reconstruction: a meta-analysis and critical review. *Plast Reconstr Surg.* 2009;124:752–764.