
Residents and Fellows: Headache Rounds

What is Currently the Best Investigational Approach to the Patient With Sudden-Onset Severe Headache?

Ane Skaare Sjulstad, MD; Karl B. Alstadhaug, MD, PhD

Key words: acute headache, subarachnoid hemorrhage, imaging, lumbar puncture, spectrophotometry, differential diagnosis

(*Headache* 2019;59:1834-1840)

Presentation of Case – Ane Skaare Sjulstad, MD, Adult Neurology Resident, Nordland Hospital, Bodø, Norway

A 48-year-old man with no previous medical history suddenly experienced severe intense retro-bulbar pain of pulsating character on the right side, and was seen in the emergency department 7 hours later. He was then alert and oriented, but in excruciating pain. There was no neck stiffness and no fever. The blood pressure was 141/80 mm Hg, and the pulse regular with a frequency of 48. Neurological examination was normal.

From the Department of Neurology, Nordland Hospital Trust, Bodø, Norway (A.S. Sjulstad and K.B. Alstadhaug); Institute of Clinical Medicine, University of Tromsø, Tromsø, Norway (K.B. Alstadhaug).

Address all correspondence to K.B. Alstadhaug, Department of Neurology, Nordland Hospital Trust, 8092 Bodø, Norway, email: Karl.bjornar.alstadhaug@nlsh.no

Accepted for publication September 5, 2019.

This is an open access article under the terms of the Creative Commons Attribution-NonCommercial License, which permits use, distribution and reproduction in any medium, provided the original work is properly cited and is not used for commercial purposes.

Query by Dr. Sjulstad:

When does actually sudden-onset severe headache represent a potential life-threatening condition?

Response by Dr. Alstadhaug:

There is no definite answer to that question. Atypical presentation of subarachnoid hemorrhage (SAH) with mild, or slowly progressive headache over minutes, and even absence of headache may occur in up to 3.8% of patients as reported in a recent Japanese study,¹ but previously up to 10% has been reported.² In a case series with 42 patients who had bled from an aneurysm, the headache came instantly in 50%, after 2-60 seconds in 24%, and within 1-5 minutes in 19%.³ In 10%-40% of patients with diagnosed bleeding from an aneurysm, there has been an episode with hyperacute headache prior to the one that led to the diagnosis.⁴ Such a warning leak has typically been reported to occur a couple of weeks earlier, but the risk of re-bleeding after SAH is highest within the first 24 hours. Non-ruptured aneurysms may also cause headache (dissection in the aneurysm wall, acute expansion or thrombosis), but more often they cause focal symptoms/signs due to mass effect

Conflict of Interest: None

or ischemia due to embolism. Thunderclap headache, hyper acute headache reaching its pain maximum within 1 minute, is the cardinal feature of SAH, but not very specific – about half of the patients with SAH experience this, but only 1 in 10 with thunderclap headache has actually bled.⁵ Thunderclap headache should always be investigated, and includes several differential diagnoses. Table 1 shows the most important causes. With a low suspicion of SAH, a good clinical judgment and a well-argued reason should underlie the decision of no further investigation of the patient. Complaints of neck stiffness are associated with a higher probability of SAH, with an estimated positive likelihood ratio of around 4, compared to patients not complaining of neck stiffness. Finding nuchal rigidity increases the probability, with an estimated positive likelihood ratio of 6.5, compared to those who have no nuchal rigidity.⁶

Different clinical tools to rule out SAH have been developed. The “Ottawa SAH Rule for Headache Evaluation” has shown to be highly sensitive for identifying SAH, but is not useful for excluding other causes of sudden-onset severe headache.⁷ Specific inclusion and exclusion criteria limit its use. Furthermore, its high sensitivity assumes that the rule is correctly applied. It is important to emphasize that the rule is constructed to help decide not to perform further investigations to rule out SAH, that it may be applied only in a limited portion of patients, and that it does not help to exclude other causes. With this and the main secondary headaches in mind (Table 1), the overall benefit of its use is questionable.

Query by Dr. Sjulstad:

When is it sufficient solely to do a conventional non-contrast CT of the head to rule out a SAH?

Response by Dr. Alstadhaug:

This is an often discussed issue in the literature. The sensitivity of detecting a SAH with conventional CT caput is dependent on when the examination is performed relative to when the bleeding occurred. Performed within 6 hours of ictus, and with a third generation CT-scanner, the negative predictive value is 99.9%-100%,⁸ and LP is in principle unnecessary in this group of patients. The sensitivity of CT decreases gradually, and after 5-7 days it is approximately 50%. Carpenter and colleagues wrote a comprehensive

systematic review and meta-analysis where they, among others, estimated the utility of supplementary investigation. In general, they found that pre-CT likelihood of SAH must be above 20% if patients were likely to benefit from a LP.⁶ In other words, a normal non-contrast cranial CT within 6 hours of thunderclap-headache onset makes supplemental investigation with LP or CTA redundant, provided that the pre-test probability for SAH is not too high. A validation study of Blok and colleagues supported this.⁹ In a retrospective study of data from 21 emergency departments over a 10-year period, Mark et al found 11 cases of SAH that had negative CT scan of the brain taken within 6 hours of ictus.¹⁰ In my opinion, there is a reason to be skeptical of claims that tests have diagnostic accuracy of nearly 100%. Technically, a modern CT-scanner would be good enough to detect a minor bleeding, and third generation CT-machines have been used in the North America since the 80s, and are available in most European hospitals. However, misinterpretation of CT (or LP) is probably the most important cause of missed diagnosis, and occurred in 15% in the series of Kowalski and colleagues.¹¹ By using proper sequences and by proper interpretation, a cerebral magnetic resonance imaging (MRI) would be as good as CT to detect SAH, and better in the subacute phase (14-16 days after bleeding occurred).¹² The lack of access, increased time consumption, and the fact that MRIs are more resource intensive, implicates that CT will still be used as a first-line investigation in near future. Some will argue that MRI with contrast (\pm arterial and venous angiography) should replace lumbar puncture as second-line investigation because SAH, as several other serious conditions, then will be captured.

A number of conditions affect the choices that the clinician makes in meeting the acute headache patient. Assessing the pre-test probability of SAH has proved difficult, but an accurate medical history is nevertheless the premise for further investigation. In a qualitative research study based on interviews of doctors in the emergency room with different experiences, Chu and colleagues identified several categories with factors that influenced the investigation.¹³ These included patient interaction, the patient's risk profile, knowledge of practice evidence, practice experience, local

Table 1.—Differential Diagnosis of Thunderclap Headache

Cause	Comments	Identifiable Primary With			
		CT	LP	CTA	MR/MRV/MRA
Diagnosis of exclusion					
Migraine, trigeminal autonomic cephalalgias, primary exercise headache, orgasmic cephalalgia and primary thunderclap headache	Supplementary investigation negative	–	–	–	–
Secondary causes					
Cerebral infarction	Acute headache is most frequent among the young patients, those with migraine, and in patients having cerebellar infarctions				+
Subarachnoid hemorrhage		+	+		
Intracerebral hemorrhage		+			
Acute subdural hematoma		+			
Colloid cyst with acute hydrocephalus	Rounded, high-attenuating mass in the anterior aspect of third ventricle, obstructing foramina of Monro	+			
Meningitis	Subarachnoid hyper-intensities on MRI-FLAIR-sequences and meningeal contrast enhancement may be seen		+		
Cervikal or intracranial artery dissection	Focal arterial stenosis and alternatively obstruction of pre-cerebral and/ or intracranial arteries			+	+
Aneurysms with mass effect symptoms				+	+
Reversible cerebral vasoconstriction syndrome	Multifocal narrowing of cerebral arteries, beaded-shaped appearance of the vessels, reversible within 3 months. Small, cortical SAH may be seen			+	
Posterior reversible encephalopathy syndrome	Hyperintense signal, mainly in the deep white matter and the back of the brain Diffusion-weighted MRI is usually normal				+
Pituitary apoplexy	CT can reveal high-attenuating signal in sella turcica if there is a hemorrhagic infarction, but normally MRI is necessary to make a diagnosis				+
Cerebral venous sinus thrombosis	MRI combined with MR venography is the preferred method, but CT venography may also be used				+
Temporal arteritis	Angiographic signs are uncommonly present			(+)	
Intracranial hypotension	Descent of the midline structures, subdural effusions and meningeal contrast enhancement				+
Hydrocephalus	Ventricular enlargement, periventricular low density signal	+			
Sinusitis	In general unspecific findings, but findings of air-fluid levels is the strongest indication of acute sinusitis	+†			
Acute narrow-angle glaucoma	Severe pain in and around the eye combined with blurry vision and seeing halos and rainbows around lights	–	–	–	–

†Must include CT of the sinuses.

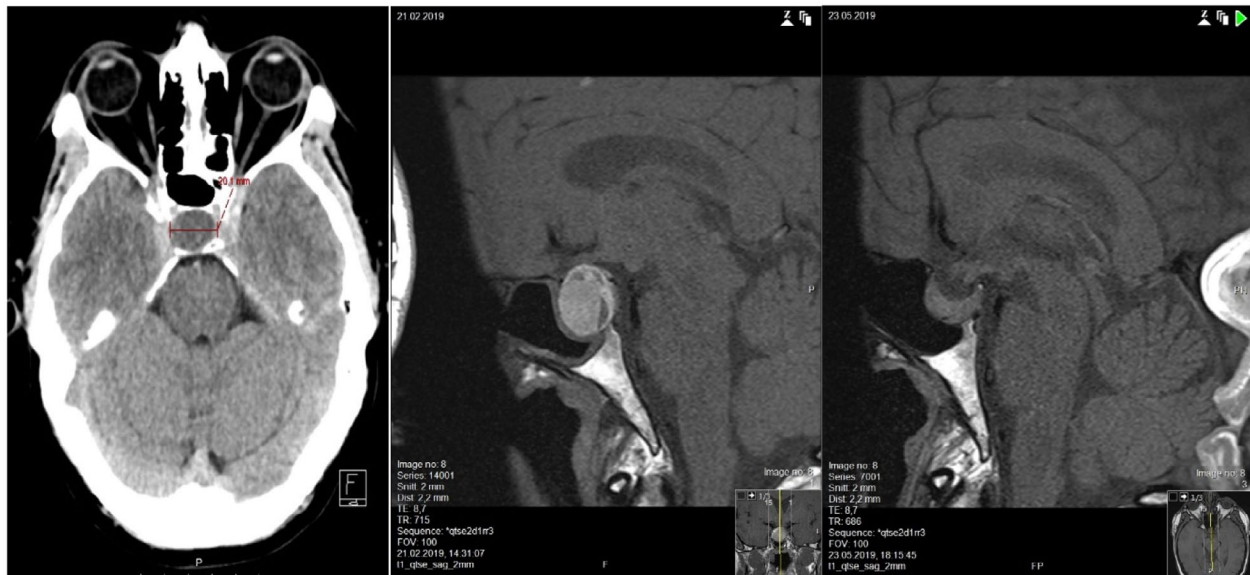


Fig. 1.—Pituitary apoplexy. Picture on the left shows an expanding mass within sella turcica on CT performed 7 hours after sudden-onset severe headache. Post contrast T1-weighted MRI (picture in the middle) shows a solid hyperintense tumor with rim enhancement and with a low signal fluid-level. Findings are compatible with a hemorrhagic apoplexy in a macroadenoma. T1-weighted MRI on the right shows regression of the tumor and no signs of bleeding three months after the event. Notice the mucosal thickening in the sphenoid sinus mucosa (picture in the middle), which probably relates to venous congestion, that later resolved (right picture). [Color figure can be viewed at wileyonlinelibrary.com]

practice, and external factors such as prompt expedition requirements.

Head-CT of the patient revealed a mass in the sella turcica (Fig. 1), but no signs of a SAH. Lumbar puncture was performed 12 hours late in accordance to international consensus. The opening pressure was normal, and standard analysis of the spinal fluid showed nothing amiss. Visually, there was no xanthochromia, but the first glass tapped was light pink. Spectrophotometry revealed a high level of oxyhemoglobin (net absorbance 0.24), and the quantification of bilirubin was then difficult. SAH could thus still not be completely excluded.

Query by Dr. Sjulstad: *Perhaps CTA can replace LP when patient presents with a headache suggestive of SAH and the CT head reveals no bleeding?*

Response by Dr. Alstadhaug:

Carpenter and colleagues suggested going directly to angiography if pre-CT probability of SAH was more than 10%. This is not insensible, since most immediate life-threatening conditions are due to vascular injury/disease, and the use of non-invasive radiology has the advantage that some diagnoses can be revealed early, eg, carotid or vertebral dissection as the cause of acute unilateral headache (Table 1). In the vast majority,

however, other symptoms and signs will accompany the headache. One exception is reversible cerebral vasoconstriction syndrome (RCVS), where about 75% has headache only. Up to 20% has a small cortical SAH that may be detected on CT or LP, and in many patients, there is no vasoconstriction in CT angiography until 1-2 weeks. Furthermore, the prognosis is usually good, and there is no established standard treatment for this condition.

Using conventional angiography as a gold standard, CTA has a sensitivity of 95%-100% to detect aneurysms ≥ 5 mm. McCormack and Hutson showed, in a mathematical model, that CT + CTA would actually work equivalent with CT and LP in the investigation of acute headache.¹⁴ Post-test probability of detecting an aneurysm bleeding was estimated at 99.4% (95% CI = 98.9% to 99.8%). The assumptions for the model were that 15% of the acute headache patients actually had SAH, that the sensitivity of CT to detect this was 91%, that 2.5% of all scanned patients would have incidental aneurysm, and that CTA would detect 99% of aneurysms >3 mm in size. These numbers can be discussed, but they are not unreasonable if this model was used strictly on patient with thunderclap

headache, which would be unlikely in clinical practice where “acute headache” is more broadly defined. The investigation method is probably not cost-effective.¹⁵ If, in reality, only 1/100 evaluated for acute headache actually has SAH, and over 90% of these will be detected with a conventional CT, one must order a minimum of 991 CTA to detect one additional aneurysm bleeding. Of these, around 20 (2%) will have a randomly detected aneurysm. Without intervention, there is no way to know if the aneurysm is what caused the headache. Furthermore, CTA can also be negative due to vessel spasm, a thrombosed aneurysm, or a structural change due to rupture. Bleeding from spinal arteriovenous malformations or aneurysms may also be overlooked. Another concern is the estimate that radiation will cause cancer in 2-3 patients per 10,000 conventional CT-scan of the brain.¹⁶ The turn to looking for vascular cause before having confirmed a vascular disaster may be convenient for the clinician, apparently good for the patient, but a great challenge for the unexperienced radiologist. In between making a choice of a needle in the back and a marginal increase in cancer risk, it is reasonable to assume that most patients will choose the latter.¹⁷ Experience also tells us that ordering an extra convenient investigation may easily breed another one. Nor should one forget that the use of contrast is potentially associated with allergy, nephro and neurotoxicity.

The patient was experiencing severe pain, nausea, and vomiting, and had bradycardia with pulse down to 25. Blood tests at admission were normal.

Query by Dr. Sjulstad:

What is the net benefit of doing lumbar puncture?

Response by Dr. Alstadhaug:

As discussed, routine use of LP has become controversial. The time from ictus to this procedure and the pre-test probability for SAH are crucial for evaluation of utility. Analogous to the calculation in the above paragraph, the numbers needed to be lumbar punctured (number needed to LP, NN_{LP}) to reveal a bleeding when early taken CT is negative are high. Sayer and colleagues reported NN_{LP} of 250 to reveal an additional aneurysm bleeding.¹⁸ Again, if the pre-test probability of bleeding is considered high, and there has been a long time since the ictus (with low sensitivity of CT as a result), then within a two-week

time window, LP will essentially be able to confirm or exclude a bleeding. The numbers must also be seen in the light of the complications of the procedure, but also of other potential benefits of examining the cerebrospinal fluid. Brunell and colleagues found that a LP could reveal an alternative diagnosis in 3% of the patients, eg, meningitis.¹⁹ Post-dural-puncture headache occurs in many, and patients with pre-morbid headaches are particularly at risk.²⁰ Rare serious complications include cerebral venous sinus thrombosis, CNS infections, and brain herniation. Traumatic lumbar tap, that is blood in the spinal fluid caused by the spinal needle, occurs in approximately 15%, and makes interpretation difficult.²¹

A new spectrophotometry of the spinal fluid was performed, and then it was clearly negative. However, light exposure may break down bilirubin and mask a minimal bleeding. A new LP will also be able to give false positive results, since one has already had a slight insertion bleeding. Based on that fact that an early CT was negative in terms of bleeding, and findings were compatible with a pituitary tumor, pituitary apoplexy was suspected. In 60%-90% of patients who get such a diagnosis, there is an underlying macroadenoma.

Query by Dr. Sjulstad:

Is spectrophotometry necessary to exclude xanthochromia?

Response by Dr. Alstadhaug:

In Norway, spectrophotometry analysis is part of the routine investigation, and used in accordance to guidelines from the UK.²² In the United States, visual inspection is mainly used. The former increases sensitivity (100%, 95% CI 59%-100%), but at the expense of specificity (95%, 95% CI 93%-96%).²³ The reason for the great variance is that different methods and cut-off values are used. According to the English guidelines, SAH is diagnosed when net bilirubin absorbance is ≥ 0.007 and net oxyhemoglobin absorbance is ≥ 0.1 . False positive samples may occur in hyperbilirubinemia and in traumatic LP. The analysis is simple and cheap. The major problem is that around 5 out of 100 tests will be false positive. How many analysis needed to be done to reveal one bleeding when CT of the brain and visual inspection of the spinal fluid are negative is largely unknown. In a study by Gangloff and colleagues, the $NN_{\text{spectrophotometry}}$ to detect an additional SAH was 706.²³

Query by Dr. Sjulstad:

When CT and LP are both negative, is the job done?

Response by Dr. Alstadhaug:

There is no doubt that the majority of adult patients who arrive at an emergency room due to acute headache have a primary headache, most often migraine. The numbers vary widely, due to diagnostic uncertainty. At a university hospital in the United States, 73% of patients with primary headache was diagnosed with non-specific headache (ICD-9 784.0). These patients received more opiates and had longer hospital stays than those with specific headache diagnosis.²⁴ How this situation in European hospitals is unknown, but there is no reason to believe that the number diagnosed with the corresponding ICD-10 diagnosis (R51) is low. Increased knowledge and awareness of differential diagnoses, with well-founded supplementary investigations, are the means to increase diagnostic specificity.

Query by Dr. Sjulstad:

Should we change routine practice?

Response by Dr. Alstadhaug:

Given the relatively low rates, but potentially very serious consequences of overlooked secondary cause of acute headaches, especially SAH, it is absolutely necessary to investigate many patients. At what price can be discussed. Textbooks, consensus attempts, and guidelines are fairly vague in terms of setting a threshold for when further investigation is unnecessary. The dogma “if you have been thinking SAH, you have to exclude SAH” still applies to a large extent. Knowledge and alertness are important pre-requisites. Which investigation algorithm to apply should be based on the starting point – a careful and correct medical history must thus be ensured. Risk profiles, symptoms, and clinical findings will also be indicative of which additional investigation that should be done. In a patient with isolated SAH-suspect headache, a negative clinical examination will not be helpful. CT of the brain, without contrast, is currently the standard 1st supplementary investigation. If this is negative, and taken within 6 hours of the ictus, the patient will have less than 1% chance of having bled. However, a LP should be done if bleeding cannot be excluded with high certainty. Replacing LP with CTA as a routine would be unfortunate as one is looking for a cause of disaster before a disaster is confirmed.

Unnecessary radiation of the patients, increased use of resources, persistent uncertainty as to whether the patient has bled or not, and the risk of finding cold aneurysms make LP the preferable 2nd supplementary investigation. However, if a vascular diagnosis other than SAH seems most probable (eg, vertebral artery dissection in unilateral headache), CTA rather than LP can be a more prudent. A negative MRI will neither rule out bleeding, nor will it be clarifying in terms of, for example infection, spontaneous low pressure headache and RCVS. MRI is not available to many, and hardly cost-effective in terms of the volume of patients to be examined. The expenses absorb the profit if you still have to do a LP. However, MRI should definitely be used when specific differential diagnoses are suspected.

MRI revealed a pituitary macroadenoma with a small hemorrhage (Fig. 1), and the patient was diagnosed with pituitary apoplexy. He received cortisone as soon as the diagnosis was established, and was transferred to the department of endocrinology where he received further substitution treatment and was successfully managed conservatively. He developed syndrome of inappropriate antidiuretic hormone secretion (SIADH) and failure of several pituitary axes.

CONCLUSION

Currently, in a patient with sudden-onset severe headache and a negative head-CT (even taken within 6 hours of ictus), we recommend a LP if SAH is still suspected. If CSF is unequivocally xanthochromic, no spectrophotometry is necessary. If the CSF is clear, colorless and acellular, or there is suspicion of a traumatic tap, the use of spectrophotometry is considered useful and reassuring. We do not recommend routinely replacing LP with CTA or MRI, but under certain circumstances LP could be avoided. Results from studies, real-world observational data, and cost-effectiveness analysis could form the basis for a possible change in this traditional investigation algorithm.

REFERENCES

1. Ogasawara Y, Ito K, Ohkuma H. Atypical presentation of aneurysmal subarachnoid hemorrhage: Incidence and clinical importance. *J Stroke Cerebrovasc Dis.* 2016;25:1208-1214.

2. Weir B. Headaches from aneurysms. *Cephalalgia*. 1994;14:79-87.
3. Linn FH, Rinkel GJ, Algra A, van Gijn J. Headache characteristics in subarachnoid haemorrhage and benign thunderclap headache. *J Neurol Neurosurg Psychiatry*. 1998;65:791-793.
4. Polmear A. Sentinel headaches in aneurysmal subarachnoid haemorrhage: What is the true incidence? A systematic review. *Cephalalgia*. 2003;23:935-941.
5. Landtblom AM, Fridriksson S, Boivie J, Hillman J, Johansson G, Johansson I. Sudden onset headache: A prospective study of features, incidence and causes. *Cephalalgia*. 2002;22:354-360.
6. Carpenter CR, Hussain AM, Ward MJ, et al. Spontaneous subarachnoid hemorrhage: A systematic review and meta-analysis describing the diagnostic accuracy of history, physical examination, imaging, and lumbar puncture with an exploration of test thresholds. *Acad Emerg Med*. 2016;23:963-1003.
7. Perry JJ, Sivilotti MLA, Sutherland J. Validation of the Ottawa Subarachnoid Hemorrhage Rule in patients with acute headache. *CMAJ*. 2017;13:E1379-E1385.
8. Dubosh NM, Bellolio MF, Rabinstein AA, Edlow JA. Sensitivity of early brain computed tomography to exclude aneurysmal subarachnoid hemorrhage: A systematic review and meta-analysis. *Stroke*. 2016;47:750-755.
9. Blok KM, Rinkel GJ, Majoie CB, et al. CT within 6 hours of headache onset to rule out subarachnoid hemorrhage in nonacademic hospitals. *Neurology*. 2015;84:1927-1932.
10. Mark DG, Hung YY, Offerman SR, et al. Nontraumatic subarachnoid hemorrhage in the setting of negative cranial computed tomography results: External validation of a clinical and imaging prediction rule. *Ann Emerg Med*. 2013;62:1-10.e1.
11. Kowalski RG, Claassen J, Kreiter KT, et al. Initial misdiagnosis and outcome after subarachnoid hemorrhage. *JAMA*. 2004;291:866-869.
12. Hodel J, Aboukais R, Dutouquet B, et al. Double inversion recovery MR sequence for the detection of subacute subarachnoid hemorrhage. *Am J Neuroradiol*. 2015;36:251-258.
13. Chu K, Windsor C, Fox J, et al. Factors influencing variation in investigations after a negative CT brain scan in suspected subarachnoid haemorrhage: A qualitative study. *Emerg Med J*. 2019;36:72-77.
14. McCormack RF, Hutson A. Can computed tomography angiography of the brain replace lumbar puncture in the evaluation of acute-onset headache after a negative noncontrast cranial computed tomography scan? *Acad Emerg Med*. 2010;17:444-451.
15. Wu X, Kalra VB, Forman HP, Malhotra A. Cost-effectiveness analysis of CTA and LP for evaluation of suspected SAH after negative non-contrast CT. *Clin Neurol Neurosurg*. 2016;142:104-111.
16. Berrington de Gonzalez A, Mahesh M, Kim KP, et al. Projected cancer risks from computed tomographic scans performed in the United States in 2007. *Arch Intern Med*. 2009;169:2071-2077.
17. Edlow JA. What are the unintended consequences of changing the diagnostic paradigm for subarachnoid hemorrhage after brain computed tomography to computed tomographic angiography in place of lumbar puncture? *Acad Emerg Med*. 2010;17:991-995; discussion 6-7.
18. Sayer D, Bloom B, Fernando K, et al. An observational study of 2,248 patients presenting with headache, suggestive of subarachnoid hemorrhage, who received lumbar punctures following normal computed tomography of the head. *Acad Emerg Med*. 2015;22:1267-1273.
19. Brunell A, Ridefelt P, Zelano J. Differential diagnostic yield of lumbar puncture in investigation of suspected subarachnoid haemorrhage: A retrospective study. *J Neurol*. 2013;260:1631-1636.
20. Alstadhaug KB, Odeh F, Baloch FK, Berg DH, Salvesen R. Post-lumbar puncture headache. *Tidsskr Nor Laegeforen*. 2012;132:818-821.
21. Shah KH, Richard KM, Nicholas S, Edlow JA. Incidence of traumatic lumbar puncture. *Acad Emerg Med*. 2003;10:151-154.
22. Cruickshank A, Auld P, Beetham R, Burrows G, Egner W, Holbrook I, et al. Revised national guidelines for analysis of cerebrospinal fluid for bilirubin in suspected subarachnoid haemorrhage. *Ann Clin Biochem*. 2008;45:238-244.
23. Gangloff A, Nadeau L, Perry JJ, Baril P, Emond M. Ruptured aneurysmal subarachnoid hemorrhage in the emergency department: Clinical outcome of patients having a lumbar puncture for red blood cell count, visual and spectrophotometric xanthochromia after a negative computed tomography. *Clin Biochem*. 2015;48:634-639.
24. McCarthy LH, Cowan RP. Comparison of parenteral treatments of acute primary headache in a large academic emergency department cohort. *Cephalalgia*. 2015;35:807-815.