



Late-onset sensory-motor axonal neuropathy, a novel SLC12A6-related phenotype

© Sissel Løseth,^{1,2} Helle Høyer,^{3,†} Kim-Mai Le,^{4,†} © Eric Delpire,⁵ Einar Kinge,⁶ Asgeir Lande,⁷ Hilde Tveitan Hilmarsen,³ Toril Fagerheim,⁸ Øivind Nilssen^{2,8} and Geir Julius Braathen³

[†]These authors contributed equally to this work.

We describe five families from different regions in Norway with a late-onset autosomal-dominant hereditary polyneuropathy sharing a heterozygous variant in the *SLC12A6* gene. Mutations in the same gene have previously been described in infants with autosomal-recessive hereditary motor and sensory neuropathy with corpus callosum agenesis and mental retardation (Andermann syndrome), and in a few case reports describing dominantly acting *de novo* mutations, most of them with onset in childhood. The phenotypes in our families demonstrated heterogeneity. Some of our patients only had subtle to moderate symptoms and some individuals even no complaints. None had CNS manifestations. Clinical and neurophysiological evaluations revealed a predominant sensory axonal polyneuropathy with slight to moderate motor components.

In all 10 patients the identical *SLC12A6* missense variant, NM_001365088.1 c.1655G>A p.(Gly552Asp), was identified. For functional characterization, the mutant potassium chloride cotransporter 3 was modelled in *Xenopus* oocytes. This revealed a significant reduction in potassium influx for the p.(Gly552Asp) substitution.

Our findings further expand the spectrum of *SLC12A6* disease, from biallelic hereditary motor and sensory neuropathy with corpus callosum agenesis and mental retardation and monoallelic early-onset hereditary motor and sensory neuropathy caused by *de novo* mutations, to late-onset autosomal-dominant axonal neuropathy with predominant sensory deficits.

- 1 Department of Neurology and Clinical Neurophysiology, University Hospital of North Norway, 9019 Tromsø, Norway
- 2 Department of Clinical Medicine, The Arctic University of Norway, 9019 Tromsø, Norway
- 3 Department of Medical Genetics, Telemark Hospital Trust, 3710 Skien, Norway
- 4 Department of Neurology and Clinical Neurophysiology, Medical Division, Akershus University Hospital, 1478 Lørenskog, Norway
- 5 Department of Anesthesiology, Vanderbilt University School of Medicine, Nashville, TN 37232, USA
- 6 Sandvika Neurocenter, 1337 Sandvika, Norway
- 7 Department of Medical Genetics, Oslo University Hospital, 0450 Oslo, Norway
- 8 Department of Medical Genetics, Division of Child and Adolescent Health, University Hospital of North-Norway, 9019 Tromsø, Norway

Correspondence to: Sissel Løseth
University Hospital of North Norway, 9019 Tromsø, Norway
E-mail: sissel.loseth@unn.no

Received May 03, 2022. Revised August 31, 2022. Accepted December 04, 2022. Advance access publication December 21, 2022

© The Author(s) 2022. Published by Oxford University Press on behalf of the Guarantors of Brain.

This is an Open Access article distributed under the terms of the Creative Commons Attribution-NonCommercial License (<https://creativecommons.org/licenses/by-nc/4.0/>), which permits non-commercial re-use, distribution, and reproduction in any medium, provided the original work is properly cited. For commercial re-use, please contact journals.permissions@oup.com

Keywords: hereditary motor and sensory neuropathy; SLC12A6 gene; autosomal-dominant inheritance; potassium chloride cotransporter 3

Introduction

Hereditary motor and sensory neuropathy (HMSN), also named Charcot Marie Tooth disease (CMT), is the most prevalent group of hereditary disorders of the peripheral nervous system (PNS).^{1,2} A wide variety of genetic variants in more than 80 different genes may cause demyelinating, axonal or intermediate forms of HMSN,^{3–5} with either autosomal-dominant, autosomal-recessive, X-linked or maternal (mitochondrial) inheritance.^{3,6} Genotype-phenotype correlations are often complex. Currently, the number of reported pathogenic variants is increasing steadily due to next-generation sequencing (NGS),^{4,7,8} and many patients previously diagnosed with a cryptogenic neuropathy may turn out to have a form of CMT.^{9,10}

Neurological findings such as polyneuropathy, hyporeflexia, foot deformities and ataxic signs can go undetected in many families due to reduced penetrance or mild symptoms, and physicians may interpret associated symptoms as unspecific neuropathy, musculoskeletal problems or orthopaedic issues, e.g. hammer toes and painful high-arched foot.¹¹ It is well known, also from other neuromuscular diseases, that variable expressivity occurs even within the same family.^{12,13} CMT usually becomes apparent in early adulthood or adolescence, but onset may also occur from childhood through late adulthood.¹⁴

The SLC12A6 gene encodes potassium chloride cotransporter 3 (KCC3), which is involved in the transport of potassium and chloride, and plays an important role in regulating cell volume and neuronal activity. KCC3 is expressed in neurons and glia cells in CNS and in sensory and motor neurons in PNS.¹⁵ SLC12A6 variants in homozygous or compound heterozygous forms are associated with Andermann syndrome (OMIM 218000), a disorder with a high prevalence in a region of Quebec in the French-Canadian population due to a founder effect.¹⁶ Also, cases outside of Canada have been reported.^{17–19} The classic Andermann syndrome is an autosomal-recessive disorder with onset in infancy characterized by a severe progressive motor and sensory peripheral neuropathy, both demyelinating and axonal, and with a variable degree of corpus callosum agenesis and mental retardation.^{16,19} A pair of fraternal twins with compound heterozygous mutations in SLC12A6, a splice variant and a gene deletion, had a much milder phenotype than usually described with recessive disease.²⁰ The twins had length dependent weakness, a length-dependent sensori-motor axonal neuropathy, third-level education and intact corpus callosum on MRI.

A few cases with different SLC12A6 dominant *de novo* mutations have been reported.^{21,22} These patients had early onset, but milder forms of demyelinating and axonal motor and to a lesser extent sensory neuropathy, normal cognition and normal cerebral MRI. A recent paper reports a male with onset in his late twenties, with an autosomal-dominant heterozygous mutation.²³ He presented with slowly progressive distal muscle weakness and atrophy, predominantly in the legs. Electrophysiological evaluations showed a mixed motor and sensory neuropathy, both demyelinating and axonal.

This report expands the genetic and clinical spectrum of SLC12A6-related disorders. In five Norwegian families with late-onset peripheral sensorimotor polyneuropathy, the identical heterozygous SLC12A6 mutation c.1655G>A p.(Gly552Asp) was

identified. To our knowledge this is the first monoallelic disease-causing mutation described in SLC12A6 that is observed in more than one generation.

Material and methods

Patients and clinical assessments

The patients lived in different regions in Norway and were seemingly not related. The families were referred to Neurological Departments on suspicion of polyneuropathy. After confirmation of the diagnosis, a genetic test for peripheral neuropathies was ordered. Additional family members were invited for a neurologic consultation and DNA analysis.

Clinical investigations were performed by a neurologist. Cranial nerves, muscle weakness, reflexes and sensation were scored according to the Neuropathy Impairment Score (NIS).²⁴ Strength is scored linearly from 0 to 4, normal strength is scored 0, paralysis is scored 4 and 25% muscle weakness, 50% muscle weakness and 75% muscle weakness are scored 1, 2 and 3, respectively. Movement against gravity, movement with gravity eliminated and muscle flicker without movement are scored 3.25, 3.5 and 3.75, respectively. Sensory deficits and reduces tendon reflexes are scored from 0 to 2 with normal findings graded 0, mildly/moderately affected modality graded 1 and severely affected modality graded 2. Ankle reflexes were scored according to the NIS guidelines: For patients 50–69 years old, ankle reflexes which are decreased are graded 0 and when absent graded 1. For patients aged ≥ 70 years, absent ankle reflexes are graded 0. Right and left limb are scored individually.

The study was approved by the local data protection officer and patients gave their written informed consent.

Nerve conduction studies and EMG

These tests were performed in different hospitals in Norway over a time period of several years, and the protocols differed to some extent. Nerve conduction studies (NCS) were performed in at least one leg and one arm in most patients. Surface electrodes were used for stimulation and registration. Motor NCS included the median, ulnar, peroneal and tibial nerves, and sensory NCS the median, ulnar, radial and sural nerves and in some patients also the superficial peroneal and medial plantar nerves. The results were compared with normal values if available by the manufacturer where the degree of abnormalities is expressed as Z-scores (number of standard deviations between obtained and expected value dependent on age and height). Z-scores of amplitudes and conduction velocities are abnormal if ≤ -2.0 . Concentric needle EMG were performed in at least one distal and often one proximal lower limb muscle on at least one side (often the tibial anterior muscle and lateral vastus muscle).

Small-diameter nerve fibre tests

Tests were performed on the affected siblings in Family I.

Quantitative sensory testing

Warm detection thresholds and cold detection thresholds were calculated as the average of 5 (Patient II-1) or 10 (Patients II-2 and II-3) consecutive temperature recordings unilaterally at the dorsum of the foot and/or on distal/lateral aspect of the leg using method of limits. Heat pain detection threshold was also determined (except in Patient II-1) as the average of five stimuli. Thresholds were compared to normal material obtained in the laboratory.

Quantification of intraepidermal nerve fibre density in skin biopsies

Two skin biopsies were obtained from the distal part of the leg, 5–10 cm above the lateral malleolus with a 3-mm disposable circular needle under local anaesthesia. Fifty-micrometre freezing sections were immunostained with the panaxonal marker PGP 9.5. The number of separate intraepidermal nerve fibres in three sections from each biopsy was counted, and the total length of epidermis was measured. Intraepidermal nerve fibre density (IENFD) in patients was compared with data from healthy individuals analysed in the same laboratory.²⁵

Molecular genetic analysis

NGS was performed as part of the routine clinical set-up. On probands from Families 1 and 2, the Illumina TruSight One Sequencing Panel was applied and sequenced on the Illumina MiSeq or NextSeq 500 platform (Illumina Inc.). The Illumina BaseSpace BWA Enrichment Workflow was used for sequence alignment and variant calling. Identified variants were interpreted through the Cartagenia Bench Lab NGS (Agilent Technologies). On probands from Families 3–5, an in-house CMT gene-specific panel was applied and sequenced on the Illumina HiScan SQ or the Illumina NextSeq 500 platforms. The Genome Analysis Toolkit (GATK) software was used for sequence alignment and variant calling. Identified variants were interpreted through the Alamut interface (Interactive Biosoftware, Rouen, France).

Verification of NGS results and co-segregation analysis in additional family members were performed by Sanger sequencing. Sanger sequencing was carried out using standard procedures and sequenced on the ABI3130XL (Life Technologies Ltd).

SLC12A6 reference sequence is given according to NM_001365088.1.

Conservation and in silico modelling

The conservation of the Gly552 residue was determined through alignment of the KCC3 protein sequence across different animal species and towards the other members of the human potassium chloride cotransporters (KCC) using HomoloGene (<https://www.ncbi.nlm.nih.gov/homologene/>) and protein BLAST (<https://blast.ncbi.nlm.nih.gov/Blast.cgi>). The modelling of the new p.Gly552Asp residue on the human KCC3 S45D/T940D/T997D in NaCl (PDB ID: 6Y5R) was performed using UCSF ChimeraX.²⁶ The position of the new amino acid change within the structure was estimated using the Rotamers tool with standard parameters.

Functional analysis

A fragment of wild-type mouse KCC3 cDNA containing an NH₂-terminal myc epitope was subcloned into a pBSK and mutated using complementary oligonucleotides and QuikChange mutagenesis kit (Agilent). The cDNA clone was fully sequenced to confirm the presence of the mutation and sequence integrity of

the overall subcloned fragment. The mutant fragment was then re-introduced into the wild-type full-length KCC3 cDNA, followed by sequencing to ensure insertion of the mutant fragment. Wild-type and mutant cDNAs were linearized using MluI digest and transcribed into cRNA for injection into *Xenopus laevis* oocytes.

X. laevis oocyte collection was done according to an approved Institutional Animal Care and Use Committee (IACUC) protocol and as described in Delpire *et al.*²⁷ and Xie *et al.*²⁸ The day after collection, oocytes were injected with 50 nl water alone or containing 15 ng transporter cRNA. The oocytes were then kept at 16°C in L15 medium (200 mOsm). Four days post-injection, groups of 25 oocytes were washed in Na⁺-free saline (200 mOsm) and pre-incubated for 10 min with 1 ml identical solution +200 μM ouabain. The solution was then aspirated and replaced with isosmotic (200 mOsm) or hypoosmotic (125 mOsm) Na⁺-free solution containing ouabain and 2.5 μCi/ml ⁸³Rb (Brookhaven National laboratories). After a 1-h uptake, the oocytes were washed four times with ice-cold isosmotic or hypoosmotic solution and individual oocytes were placed in vials with 200 μl 0.5N NaOH for 1 h, then neutralized with the addition of 100 μl acetic acid glacial. Liquid scintillation fluid (5 ml) was added to the vials and radioactive ⁸³Rb was counted using a Perkin Elmer Tri-carb 2910TR liquid scintillation counter. Aliquots of 5 ml uptake solution were also counted to relate counts per minute (cpm) to the amount of K⁺ in the solution. K⁺ influx was expressed in pmoles K⁺/oocyte/h.

Groups of 10 oocytes were also lysed (30 μl/oocyte) in a buffer containing 150 mM NaCl, 50 mM Tris (pH 8.5), 2 mM EDTA, 0.1% sodium dodecyl sulphate (SDS), 0.5% Na-12 deoxycholate and 1% CHAPS and equal amounts of lysates (40 μl) were loaded and subjected to SDS-polyacrylamide gel electrophoresis and western blot analysis. Primary and secondary antibodies used were mouse anti-myc monoclonal (mouse monoclonal, clone 9E10 from Thermo Fisher Scientific) and horse radish peroxidase-conjugated anti-mouse antibody.

Data availability

Data supporting the findings of this study are available within the article and its [Supplementary material](#). Supporting data in this study are available from the corresponding author upon request. To safeguard patient privacy, individual participant data beyond those reported in this article will not be shared. The SLC12A6 variant has been submitted to the ClinVar database (<https://www.ncbi.nlm.nih.gov/clinvar/>), accession number SCV002037215.

Results

Patients and families

Pedigrees are presented in [Fig. 1](#). [Table 1](#) presents the clinical characteristics of affected individuals (detailed NIS scores are presented in [Supplementary Table 1](#)). [Table 2](#) presents the neurophysiological data.

Family 1

The proband (Patient II-3), a 30-year-old male from a non-consanguineous family, had during the past 2 years experienced numbness in both legs, especially when lying down and stretching his feet. For a short period, he had also felt numbness at the ulnar aspect of the left hand. As long as he could remember, his feet often tended to get cold and sweaty. He reported the motor functions to be normal. On clinical examination there was almost no motor

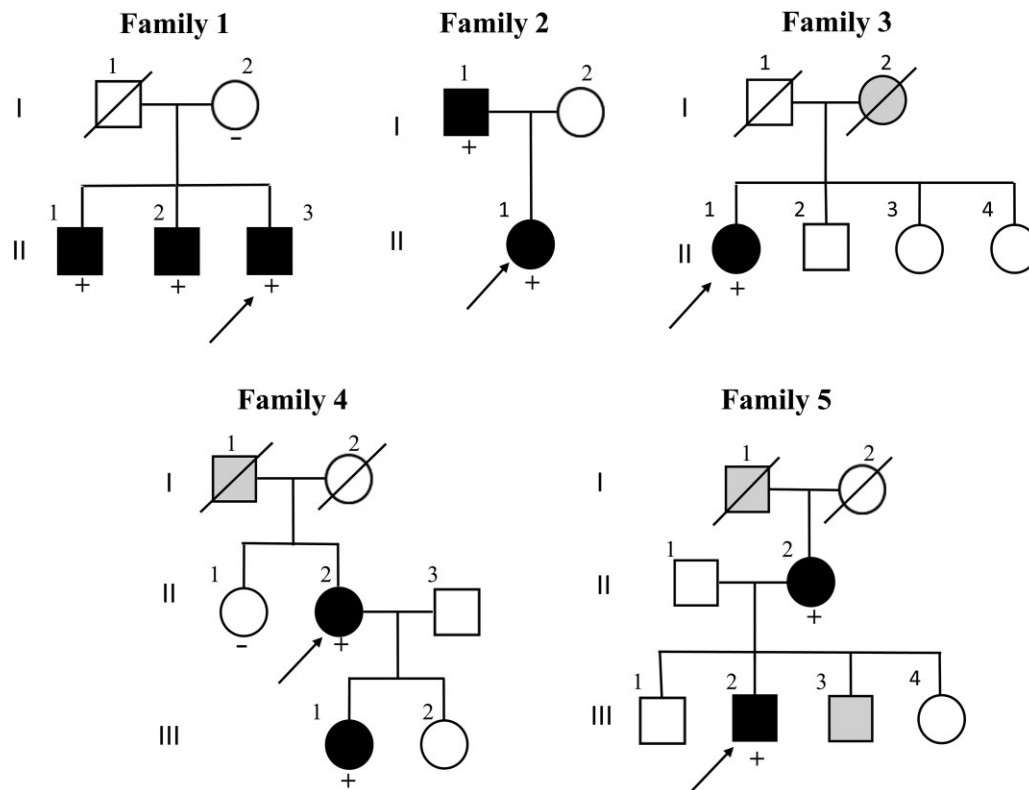


Figure 1 Family pedigrees. The probands are indicated by arrows. Black-filled symbols indicate clinical and neurophysiological diagnosis of neuropathy. Grey-filled symbols indicate anamnestic information that could indicate polyneuropathy. Individuals with the *SLC12A6*: c.1655G>A p.(Gly552Asp) sequence variant are marked with a plus symbol, and those with wild-type *SLC12A6*: c.1655G=p.(Gly552=) are marked with a minus sign symbol.

impairment. Testing of sensory function revealed more selective involvement of large fibre function: vibration sense was severely reduced, while pinprick sensation was intact. Deep tendon reflexes were absent. Romberg's test was positive when closing his eyes. His two older brothers (Patients II-1 and II-2) were healthy and had no symptoms, either sensory or motor. They had full-time jobs which required good motor skills. On clinical examination the findings were almost identical as in the proband (Table 1). NCS showed the same pattern in the three brothers: a pronounced symmetrical sensory axonal polyneuropathy with absent or nearly absent sensory responses and almost no motor involvement (Table 2). EMG revealed a mild chronic neurogenic pattern in the proband. In his siblings (Patients II-1 and II-2), the degree of neurogenic changes was even milder. Thermal perception thresholds were normal (Table 3), and they reported no allodynia. IENFDs were normal except slightly reduced in one of the non-symptomatic siblings (Table 3).

The proband was re-evaluated after 9 years. The symptoms and findings on clinical examination were similar and neurophysiological examination did not reveal any significant progression (data not shown). The two older brothers were interviewed by telephone almost 10 years after the initial investigations. They still did not have any sensory or motor symptoms suggestive of a peripheral neuropathy.

Their mother did not carry the mutation. She was asymptomatic with normal clinical neurological examination and normal NCS (data not shown). Their father had died from cancer in his sixties. He had for many years lived abroad, and his health condition was unknown.

Family 2

Both father (Patient I-1) and daughter (Patient II-1) were only children. The daughter was diagnosed with axonal sensory and motor neuropathy at the age of 42. As long as she could remember, she had tended to stumble, but the problem had recently worsened. She also complained of numbness in her feet and legs in addition to slight unsteadiness. Aged 44, she stumbled and fractured her right ankle. On neurological examination at the age of 46 years she had a mild sensory ataxia, slightly reduced pain and touch sensation in her feet, mild to moderate reduction of vibration sense and proprioception distal in the feet in addition to hyporeflexia. During Romberg's test, she had to steady herself 5 s after closing her eyes. Brain CT scan was normal.

Her father was referred to a neurologist when he was almost 70 years old. At that time, he had become increasingly unsteady for the past 4 years. He reported no sensory symptoms. Clinically he had more distal motor deficits than his daughter (Table 1). He presented with mild muscle wasting in both feet and legs, moderate muscle weakness for toe and ankle plantar- and dorsiflexion, slightly reduced vibration sense in ankles and toes and slightly reduced proprioception in toes. He had hyporeflexia in the upper limbs and areflexia in the lower limbs. Romberg's test was positive. He was not able to walk in a straight line or walk on his toes or heels. Brain MRI revealed no abnormalities except moderate age-related changes.

In both, NCS showed a pronounced sensory axonal symmetrical polyneuropathy with no evocable sensory responses in arms and legs with a distal nearly symmetric axonal motor component,

Table 1 Demographic data and clinical characteristics

Family	1		2		3		4		5	
	II-1	II-2	I-1	II-1	II-1	II-2	III-1	II-2	III-2	Male
Gender	Male	Male	Male	Female	Male	Female	Female	Female	Male	6
Age at first symptom	No symptoms	No symptoms	65	37	6	34	22	45	6	
Age at investigation	39	38	69	46	59	53	23	82	50	
Muscle wasting ^a	0	0	1: hand and foot	0	1: hand and foot	1: hand and foot	1: hand and foot	0	0	0
Muscle weakness ^a	0	0	1: ankle plantar- and dorsiflexion, toe extension and flexion	0	1: finger spread, thumb abduction, ankle plantar- and dorsiflexion, toe extension and flexion	1: shoulder abduction, elbow flexion, wrist extension, finger spread and flexion	1: hand and foot 1: finger flexion, finger spread, thumb abduction (feet not investigated)	0	0	0
Sensory loss, touch ^a	1: leg, foot 2: finger, toe	1: foot 2: finger, toe	0	1: foot, toe	1: leg, foot, toe	0	1: finger, toe	1: leg 2: foot and toe	1: forearm, leg 2: hand, finger, foot, toe	
Sensory loss, pain ^a	0	0	0	1: foot, toe	1: forearm, hand, finger, leg, foot, toe	1: forearm, hand, finger, thigh 2: leg, foot, toe	1: finger, toe	1: leg 2: foot and toe	1: forearm 2: hand	
Sensory loss, vibration ^a	1: finger, ankle 2: metatarsal, toe	1: finger, knee 2: ankle, metatarsal, toe	1: ankle, metatarsal, toe	1: ankle 2: metatarsal, toe	2: hand, finger, knee, ankle, metatarsal, toe	2: hand, finger, knee, ankle, metatarsal, toe	1: toe	2: ankle, metatarsal, toe	-	
Sensory loss, proprioception ^a	1: finger 2: toe	2: toe	1: toe	1: toe	1: toe	1: finger 2: toe	0	-	-	
Reflexes	Areflexia except hyporeflexia patellar	Areflexia	Hyporeflexia arm, areflexia leg	Hyporeflexia except achilles	Hyporeflexia arm, areflexia leg and biceps	Normal arm, areflexia leg	-	Areflexia	Hyporeflexia arm, areflexia leg	
Deformities	-	Pes planus, hallux valgus	Pes cavus	Pes cavus	Pes cavus, hammer toes	Scoliosis, pes cavius, hammer toes	-	0	-	
NIS ^b	38	38	24	21	42	72.5	-	28	30	

^a0 = Normal; 1 = mildly/moderately affected modality; 2 = severely affected modality; (-) = not informative. Symmetric unless specified.

^bFor details see [Supplementary Table 1](#).

Table 2 Neurophysiology in affected probands carrying the SLC12A6 variant

Family	1			2		3	4		5	
	II-1	II-2	II-3	I-1	II-1	II-1	II-2	III-1	II-2	III-2
Age at examination	39	38	30	69	46	57	59	36	82	51
Motor nerves ^a										
Median CMAP	6.5	9.4	7.6	5.6	7.6	N	4.6	4.6	3.9	8.9
CV	50.0 (-2.3)	48.0 (-2.8)	48.0 (-2.8)	51.2	52.3	57.6	44.8 (-4.4)	51.8	50.8 (-2.1)	54.3
Ulnar CMAP	8.1	6.3	7.1	5.2	7.5	-	5.2	7.8	7.2	-
CV	46.6 (-2.8)	47.7 (-2.6)	46.7 (-2.8)	52.4	51.8		45.3 (-3.1)	51.0 (-2.0)	50.4 (-2.1)	
Peroneal CMAP	4.7	4.4	8.7	0.2 (-2.3)	0.4 (-2.3)	N	0.5 (-2.3)	5.3	1.8	3.8
CV	42.5	42.0	50.7	36.9	36.5 (-2.8)	40.2	37.5 (-2.4)	44.8	39.2	42.9
Tibial CMAP	15.3	5.6	15.7	0.3 (-2.1)	1.1 (-2.6)	-	3.9	6.6	2.3	13.3
CV	42.3	41.5	45.2	34.9 (-2.0)	39.3		36.4 (-2.2)	45.0	39.7	42.9
Sensory nerves ^a										
Median SNAP	3.6 (-6.8)	2.2 (-7.8)	A	A	A	A	2.1 (-7.3)	8.8 (-5.9)	A	4.1 (-6.5)
CV	48.2 (-2.2)	46.8 (-2.5)					42.4 (-2.6)	51.0		40.0 (-3.2)
Ulnar SNAP	A	A	1.4 (-5.5)	A	A	A	A	3.7 (-4.3)	A	-
CV			33.3 (-4.5)					54.8		
Radial SNAP	A	A	A	A	A	-	1.4 (-6.4)	5.4 (-4.3)	A	2.8 (-4.0)
CV							43.1 (-3.9)	59.1		48.0
Sural SNAP	A	1.3 (-3.8)	A	A	A	A	-	1.12 (-5.0)	A	A
CV		43.8						53.6		
Sup peroneal SNAP	A	A	A	A	A	-	A	2.4 (-2.7)	A	A
CV								49.0		
Med plantar SNAP	-	A	A	-	-	-	-	-	A	A
EMG ^b	+	+	-	++	+	+	+	n	+	-

Abnormal values in bold (Z-scores in parenthesis taking age and height into account). A = absent response; CMAP = compound muscle action potential amplitude (mV); CV = conduction velocity (m/s); N = normal amplitude not specified; SNAP = sensory nerve action potential amplitude (μ V); (-) = not measured.

^aRight side.

^bElectromyographic findings in tibial anterior muscle: n = normal; (+) = mild neurogenic; (++) = moderate neurogenic.

more severe in the father (Table 2). Needle EMG in the father showed a moderate chronic neurogenic pattern in the tibial anterior muscle and lateral vastus muscle with slight to moderate denervation, while in the daughter the neurogenic changes were milder.

Family 3

The proband, Patient II-1, stumbled and fell more than other persons of same age from age 5–6 years. The disorder progressed slowly with more frequent falls from age 35 years. At age 50 she experienced paresis in feet and legs and 5 years later also in hands. Her focus was her frequent falls and not her motor and sensory deficits at time of investigation. Table 1 resumes her neuropathic signs at age 59 years. NCS at age 57 showed findings consistent with a pronounced symmetric sensory axonal polyneuropathy. Needle EMG showed slight to moderate neurogenic changes in the anterior tibial anterior muscles and vastus lateral muscles bilateral.

Her mother, deceased and never investigated, had similar age at onset, symptoms and disease course with prominent gait problems after age 80–85.

Family 4

The female proband (Patient II-2), previously a competitive cross-country skier, had symptom debut at 49 years old with distal paraesthesia, and a diagnosis of sensorimotor polyneuropathy was verified on NCS the following year. There was a slow yet steady symptom progression over the next 15 years, with predominantly sensory symptoms, and subsequent weakness, areflexia, ataxia, gait problems and tremor. She was also followed by a rheumatologist for Sjogren's syndrome. The proband's daughter (Patient III-1)

Table 3 Quantitative sensory testing and skin biopsy in Family 1

Patient	II-1	II-2	II-3	Normal values
QST				
WPT foot ($^{\circ}$ C)	40.2	38.8	38.8	<44.0
CPT foot ($^{\circ}$ C)	28.1	28.3	28.5	>25.5
WPT leg ($^{\circ}$ C)	-	32.9	33.7	<40.5
CPT leg ($^{\circ}$ C)	-	28.3	28.4	>26.0
HPDT leg ($^{\circ}$ C)	-	43.4	41.0	>40.5 < 47.5
Skin biopsy				
IENFD (fibres/mm)	7.0	4.9	12.3	>5.6

CPT = cold perception threshold; HPDT = heat pain detection threshold; QST = quantitative sensory testing; WPT = warmth perception threshold. Abnormal value in bold.

had distal paraesthesia and numbness in hands and feet from 22 years of age, and clinical examination the same year revealed decreased peripheral sensibility and mildly reduced strength in both hands. NCS showed a mild, predominantly sensory axonal neuropathy. The symptoms were stable during the next 10–12 years, and subsequently accelerated slowly both clinically and on neurophysiological investigation. The proband's father (Patient I-2) was probably affected with polyneuropathy according to anamnestic information, but thorough diagnostic workup and genetic testing were not performed. He died at 79 years old. The proband's sister had no symptoms of polyneuropathy and genetic testing confirmed that she did not have the family's variant in SLC12A6. The proband's daughter (Patient III-2) has symptoms compatible with peripheral neuropathy, but has not been thoroughly investigated due to substantial comorbidity.

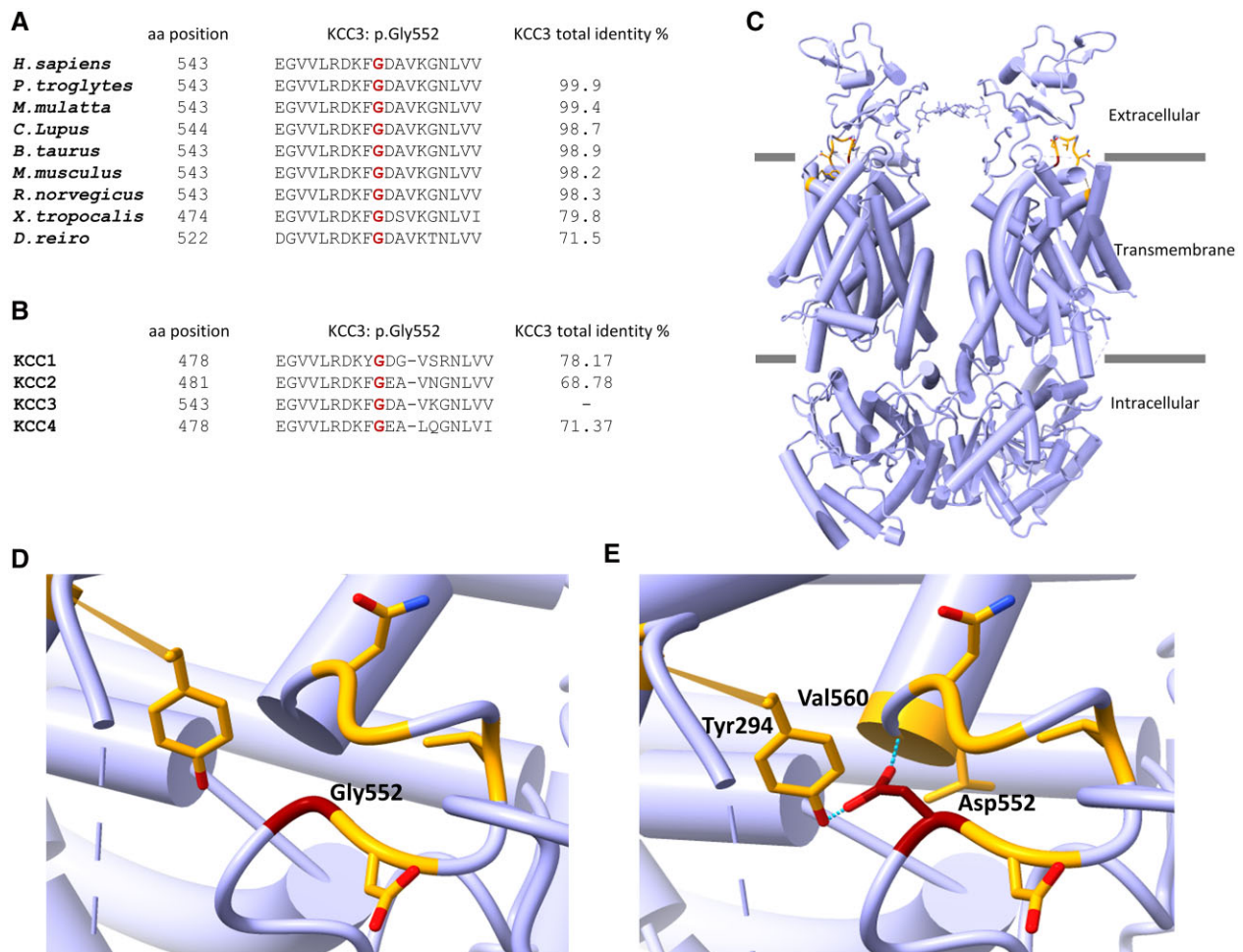


Figure 2 Conservation and in silico modelling. (A) Evolutionary conservations of the amino acid (aa) affected by the novel p.Gly552Asp mutation within KCC3 across different species. (B) Paralogue conservation of the human KCC3 p.Gly552 residue among the different members of the human potassium chloride cotransporters (KCC). (C) Cartoon modelling of the human KCC3 homodimer based on PDB:6Y5R. The Gly552 residue is shown in dark red and the interacting residues in orange. (D) Localization of the Gly552 residue (dark red) and its interacting amino acids (orange). Based on PDB:6Y5R. (E) Localization of the Gly552Asp substitution (dark red), interacting amino acids (orange) and the predicted formation of two new hydrogen bonds (dotted lines) with Tyr294 and Val560. Based on PDB:6Y5R.

Family 5

Since early childhood the proband (Patient III-2) had complained of numbness in his legs and modest unsteadiness. The diagnosis of polyneuropathy was confirmed in his twenties. NCS showed mild abnormalities. In his thirties he also developed impaired finger sensitivity. Findings on clinical examination at the age of 50 are presented in Table 1. Musculoskeletal examination revealed a generalized pain syndrome with tenderness over both trochanter regions, gluteal regions and thoracic part of his back. His gait was stiff and unsteady. NCS showed a pronounced symmetrical sensory axonal polyneuropathy (Table 2). The motor amplitudes were normal, and EMG showed very mild neurogenic changes in the tibial anterior muscle but normal findings in proximal muscle in lower limb.

The proband's mother (Patient II-2) had complained of feeling cold in her legs since childhood; later she had ascending loss of sensitivity and numbness in her feet. In adulthood she also experienced slowly increasing weakness of the legs and an unsteady gait. She was diagnosed with polyneuropathy in her fifties at her local hospital and received B₁₂ treatment. The symptoms had stabilized. On clinical examination at 82 years old there was no paresis

and no muscular atrophy but reduced peripheral sensibility in legs, in particular distally, and an unsteady gait. Deep tendon reflexes were absent in both upper and lower limbs. NCS showed a pronounced symmetrical sensory axonal polyneuropathy with absent sensory responses, and in addition a very mild motor component (Table 2). The proband's brother (Patient III-3) and the mother's father (Patient I-1) had symptoms suspicious of polyneuropathy, but they were never investigated.

Genetic testing

At the University Hospital of North Norway, extensive testing by Sanger sequencing for mutations in genes involved in axonal and demyelinating HMSN and hereditary neuropathy with pressure palsies performed for Families 1 and 2 gave negative results. Upon NGS-based DNA analysis of affected individuals in the two families, they were all found to be heterozygous for the sequence variant c.1655G>A, p.(Gly552Asp), situated in exon 14 of the SLC12A6 (NM_001365088.1) gene.

At Telemark Hospital Trust, NGS-based DNA analysis was performed for Families 3 and 4 in 2012 and Family 5 in 2016. The

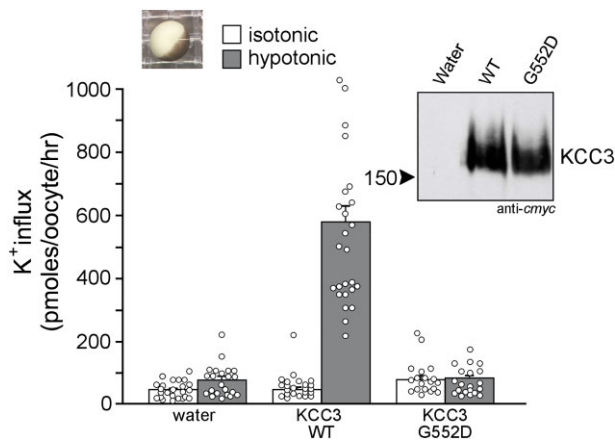


Figure 3 Functional analysis of KCC3. Absence of KCC3-Gly552Asp function in *X. laevis* oocytes. K^+ influx was determined in oocytes injected with water, wild-type KCC3 and KCC3-G552D mutant under isosmotic (white bars) or hypoosmotic (grey bars) conditions. Bars = mean \pm SEM ($n = 23$ – 26 oocytes). Right inset: Picture of a defolliculated stage VI *X. laevis* oocyte under dissecting microscope. Left inset: Western blot analysis of cmyc-tagged transporter showing absence of signal in water-injected oocytes and equivalent signal in wild-type versus mutant KCC3-injected oocytes.

SLC12A6 variant c.1655G>A was detected but classified as likely benign based upon reports of autosomal recessive inheritance in KCC3-related disease. Upon a genetic re-evaluation of Family 3 in 2017, the SLC12A6 variant was reclassified as a variant of unknown significance, based on newly published literature describing cases who were heterozygous for *de novo* mutations.²¹ Sanger sequencing showed that the variant was carried by the affected daughter in Family 3.

By combining DNA results from the two centres, it became clear that in total 10 affected individuals from five families carried the SLC12A6 c.1655G>A variant. The variant segregates with all affected individuals and was not present among two unaffected individuals.

The variant is absent from large population databases, i.e. more than 250 000 SLC12A6 alleles annotated in GnomAD and 13 000 alleles annotated in esp6500. The variant is not present in the Norwegian Variant Frequency database (<https://variant.norgene.no/>) containing 5710 alleles. However, as for the latter database allele counts below five were filtered out to ensure anonymity of personal data in compliance with the EU general data protection regulation. The variant has not previously been detected at two other Norwegian genetic reference centres in Oslo and Bergen (personal communication, May 2021).

The five families presented in this study are seemingly unrelated based on available genealogical information. However, the probands of Families 2, 3, 4 and 5 share a rare intronic single nucleotide variant in the SLC12A6 gene (hg19 Chr15:34528850A>G), situated 9.2 kb upstream the reported c.1655G>A (p.(Gly552Asp)) variant. The shared intronic variant is not present in GnomAD and the Norwegian Variant Frequency database. This strongly indicates that the four probands share a rare haplotype of common ancestral origin.

Conservation and in silico analysis

The Gly552Asp substitution targets a residue that is both conserved evolutionarily (Fig. 2A) and among the three other human KCC

family members (Fig. 2B). *In silico* modelling on KCC3 in NaCl show that the p.Gly552Asp variant is situated in a loop at the interface between the transmembrane and extracellular domain (Fig. 2C). The substitution from glycine to aspartic acid causes a side chain alteration from a single hydrogen atom to a negatively charged side chain. The substitution is predicted to create two new hydrogen bonds with Tyr294 and Val560, leading to potential structural and/or functional effects (Fig. 2D and E).

Functional analysis

To assess the effect of the mutation on KCC3 activity, we expressed wild-type and mutant transporter in *X. laevis* oocytes and measured K^+ influx (expressed in pmoles K^+ /oocyte/h). As seen in Fig. 3, K^+ influx in wild-type KCC3-injected oocytes is similar to water-injected oocytes under isosmotic conditions. The KCC3-mediated K^+ influx is stimulated by hypotonicity. Replacement of Gly552 into aspartic acid completely abrogated cotransporter function. Oocytes injected with wild-type or mutant SLC12A6 cRNA demonstrated equal KCC3 expression levels. Supplementary Fig. 1 shows the unmodified full-length gel.

Variant classification

The American College of Medical Genetics and Genomics (ACMG) and The Association for Clinical Genomic Science (ACGS) criteria are intended for classification of sequence variants in genes firmly established as causes for Mendelian disorders.^{29,30} Although SLC12A6 has not previously been associated with autosomal-dominant late-onset neuropathy, we present a criteria-based classification of the pathogenicity of c.1655G>A, constituting a brief summary of our data: PS3 moderate (functional studies indicate loss of cotransporter function), PP1 strong [co-segregation through seven informative meiosis in a total of four families, $n = (1/2)^7 = 1/128$], PP3 supportive (the variant is conserved in paralogue and orthologue domains), and PM2 moderate (the variant has no frequency in population databases) classify c.1655G>A as a likely pathogenic variant.

Discussion

In this study, we present five families with adult-onset predominant sensory axonal polyneuropathy caused by a novel heterozygous variant in the SLC12A6 gene. The SLC12A6 variant was present in 10 affected family members while two unaffected family members did not have the variant.

Phenotypic, clinical and neurophysiological considerations

The clinical manifestations and debut of symptoms varied to some extent, even within the same family. A few patients reported some neuromuscular symptoms in childhood, but no one were referred to a neurologist until adult age (the earliest at 22 years of age, the latest at almost 70), indicating that the initial symptoms were mild and the disease progression was slow. Symptoms varied from very mild to prominent, more sensory than motor in most patients, with a distal to proximal gradient. Interestingly, the siblings of the proband in Family 1 were asymptomatic even into their forties, although clinical evaluation and neurography revealed abnormal findings. No one complained of neuropathic pain. CNS symptoms were not present in any patient.

Table 4 Dominant heterozygous variants in the SLC12A6 gene in ascending order, predicted protein change and overall clinical characteristics

	Shi et al. ²³	Park et al. ²²	This study	Park et al. ²²	Kahle et al. ²¹
Genotype	c.620G>A	c.620G>A	c.1655G>A	c.203A>G	c.2971A>G
Protein change	p.Arg207His	p.Arg207His	p.Gly552Asp	p.Tyr679Cys	p.Thr991Ala
Ethnicity	Chinese	German	Norwegian	German	American
Number of families	1	2	5	1	1
Number of patients	1	2	10	1	1
Age at onset, years	27	1–2	6–65 (8)	1–2	1
Observation period ^a	4	9–10	1–53 (8)	13–14	9
Disease progression	Yes	Yes	Yes (7)/No (3)	Yes	Yes
Motor development	Normal	Delayed	Normal	Delayed	Delayed
Muscular atrophy	Distal LE	Distal LE and UE	Distal LE and UE (4)	Distal LE	Distal and proximal LE and UE
Paresis	Distal LE	Distal > proximal LE and UE	Distal (5)	Distal LE and UE	Distal > proximal LE and UE
Spasticity	No	No	No	Yes	No
Sensory findings	Distal LE	None-minor	Yes (10)	Periumbilical hypoaesthesia	No
Scoliosis	No	Yes (1)	No	No	–
Neuropathy characteristics	Predominant demyelinating sensorimotor	Predominant demyelinating, sensorimotor	Predominant axonal and sensory	Predominant axonal, sensorimotor	Predominant axonal and motor
Median nerve motor CV, m/s	41–42	32–35	Normal or 45–51	Normal	31
Median nerve sensory CV, m/s	31–34	Absent and 21	Absent or 40–51	Normal	44
Brain MRI	Normal	Normal	Normal (1)	Normal	Normal

The number of patients with signs are in parentheses. For details see individual references and Tables 1 and 2 in this study. CV = conduction velocity; LE = lower extremities; UE = upper extremities; (–) = not informative.
^aNumber of years from age at onset to age at investigation/evaluation.

On clinical examination all 10 affected family members had sensory and reflex abnormalities, while five patients had muscle weakness, most pronounced distally. The partition of NIS into NIS motor, NIS sensory and NIS reflexes revealed that overall NIS mostly consisted of the sensory and reflex findings. Only one patient (II-2 in Family 4) had prominent muscle weakness consistent with a severe CMT phenotype and a high NIS value.

On NCS a common finding was absent or almost absent sensory responses, and often the motor nerves were involved to a much lesser extent, consistent with an axonal neuropathy with dominating sensory involvement. The pronounced sensory abnormalities on NCS in some patients were in contrast to the very mild (or even no) symptoms. Supplemental tests in Family 1 (quantitative sensory testing and skin biopsy) showed almost sparing of the small diameter nerve fibres. Sural nerve biopsy was not performed.

The phenotype in our families differs compared to other cases with *SLC12A6* biallelic or heterozygous *de novo* mutations reported elsewhere. First of all, in most patients described previously, the first manifestations are in infancy or early childhood with motor disabilities that could be severe, and also mental retardation in Anderman syndrome.^{16,21,22} NCS in these children have shown a motor and sensory polyneuropathy (motor often dominate), mixed axonal and demyelinating. To our knowledge only one paper reports a patient with onset in his twenties.²³ He had both motor and sensory impairment clinically, and NCS showed a predominant demyelinating polyneuropathy.

The phenotypic heterogeneity among patients with dominant *SLC12A6* variants is highly variable based on previous literature^{21–23} and this report (Table 4). Our families reveal a milder phenotype than previously described. It could be speculated that the different dominant variants have different disease mechanisms or that some variants might be milder (hypomorphic). As discussed below, specific variants have different consequences for KCC3 channel function.^{21–23} Further, it is well known that genetic disorders with both juvenile and adult onset often display variable disease severity probably due to the influence of other genetic and environmental factors impacting penetrance and clinical expression.³¹

Genetics, variant interpretation and functional analysis

The *SLC12A6* c.1655G>A, p.(Gly552Asp) variant is extremely rare because it is absent from >250 000 *SLC12A6* alleles annotated in the Genome Aggregation Database (gnomAD) as well as among 13 000 alleles annotated in esp6500, and 5710 alleles in the Norwegian Variant Frequency database (<https://variant.norgene.no/>). Hence, it is very unlikely that the *SLC12A6* c.1655G>A allele seen in five Norwegian families has occurred through recurrent mutational events. Instead, it supports the idea that these families share a common ancestor.

Together with the other three KCC, KCC3 is involved in maintaining intracellular Cl⁻ levels and in regulating cell volume through electroneutral efflux of potassium and chloride and diffusion of water molecules. The transporter is not active under isotonic conditions but becomes active when the cell is subjected to hypotonic conditions.³⁰ In contrast to wild-type KCC3, *in vitro* analysis demonstrated that the mutant KCC3-Gly552Asp transporter is non-functional when expressed in *X. laevis* oocytes. This is in line with two other dominantly acting substitutions shown to be dysfunctional.²¹ The p.Gly552Asp substitution is localized in a loop at the interface between the extracellular and transmembrane domain. Interestingly, the substitution is located two positions upstream to a key lysine that forms a salt bridge with an aspartic acid keeping the extracellular gate closed in all KCC.²⁸

Biallelic mutations in *SLC12A6* are involved in Anderman syndrome (HMSN/ACC) through loss of KCC3 function.^{19,32} With the exception of two missense variants, all mutations known to cause biallelic HMSN/ACC are true loss-of-function or splice site mutations predicted to undergo nonsense-mediated decay (based upon HGMD Professional version 2021.3). Heterozygous carriers are healthy, indicating that haploinsufficiency at the gene level, leading to protein expression from one allele only, does not cause disease. Including the mutation c.1655G>A, reported here, three other heterozygous missense mutation have been shown to cause dominantly acting KCC3-related disease.^{21–23} The first published variant, p.(Thr991Ala), resulted in constitutive KCC3 activity and likely a gain of function effect.²¹ The two other published variants, p.(Arg207His) and p.(Tyr679Cys) as well as the variant presented here completely or partly caused loss of KCC3 function.^{22,23}

As KCC3 functions as a homodimer, theoretically 75% of the transporters contain mutant proteins when the disease-causing variant is translated and expressed. Although haploinsufficiency causing about 50% reduction of functional KCC3 homodimers is likely not sufficient to cause disease, a 75% reduction could be disease-causing, but with reduced severity and later onset as compared to previously described HMSN/ACC where there is mostly 100% reduction. It is also observed in some other neuromuscular genes that biallelic variants may cause a more severe early-onset phenotype whereas the monoallelic variant causes later onset and milder phenotype, such as those observed for *STUB1*,^{33,34} *MME10* and the aminoacyl-tRNA synthetase genes *AARS1*, *GARS1*, *HARS1*, *WARS1* and *YARS1*.³⁵

To conclude, our families expand the spectrum of CMT and neuropathy phenotypes associated with heterozygous mutations in the *SLC12A6* gene. Patients presented with a milder phenotype than previously reported, and a slowly progressive sensory or sensorimotor axonal neuropathy. CNS manifestations were not present. This work demonstrates for the first time a heterozygous *SLC12A6* pathogenic variant that is inherited through generations.

Acknowledgements

We thank the participating patients and their families for their cooperation. Regarding the processing and analysis of the skin biopsies, we would like to thank senior engineer Edel Olsen, Professor Sigurd Lindal and Professor Svein Ivar Mellgren, Neuromuscular Diseases Research Group, The Arctic University of Norway, Tromsø, Norway. We thank Biomedical Laboratory Scientist Monica Ingebrigtsen for verifying *SLC12A6* c.1655G>A in Families 1 and 2 and senior engineer Gry Beate Namløs Nordang and engineer Ewelina Rojek-Jenssen for verifying *SLC12A6* c.1655G>A in Families 3–5. We would also like to thank clinical neurophysiologist Uliana Brobakken for providing NCS data in Family 5.

Funding

E.D. is funded by NIH grant R01 DK93501 and by Leducq foundation grant 17CVD05.

H.H. is funded by the Helse Sør-Øst RHF: research grant #2021097.

Competing interests

The authors report no competing interests.

Supplementary material

Supplementary material is available at *Brain* online.

References

- Braathen GJ, Sand JC, Lobato A, Hoyer H, Russell MB. Genetic epidemiology of Charcot–Marie–Tooth in the general population. *Eur J Neurol*. 2011;18:39–48.
- Barreto LC, Oliveira FS, Nunes PS, et al. Epidemiologic study of Charcot–Marie–Tooth disease: A systematic review. *Neuroepidemiology*. 2016;46:157–165.
- Bird TD. Charcot–Marie–Tooth hereditary neuropathy overview. In: Adams MP, Ardinger HH, Pagon RA, et al. *GeneReviews*. University of Washington;1993–2022. <https://www.ncbi.nlm.nih.gov/books/NBK1358/>
- Pareyson D, Saveri P, Pisciotta C. New developments in Charcot–Marie–Tooth neuropathy and related diseases. *Curr Opin Neurol*. 2017;30:471–480.
- Stavrou M, Sargiannidou I, Christofi T, Kleopa KA. Genetic mechanisms of peripheral nerve disease. *Neurosci Lett*. 2021;742:135357.
- Skre H. Genetic and clinical aspects of Charcot–Marie–Tooth’s disease. *Clin Genet*. 1974;6:98–118.
- Klein CJ. Charcot–Marie–Tooth disease and other hereditary neuropathies. *Continuum (Minneapolis)*. 2020;26:1224–1256.
- Tazir M, Hamadouche T, Nouioua S, Mathis S, Vallat JM. Hereditary motor and sensory neuropathies or Charcot–Marie–Tooth diseases: An update. *J Neurol Sci*. 2014;347(1–2):14–22.
- Currò R, Salvalaggio A, Tozza S, et al. RFC1 expansions are a common cause of idiopathic sensory neuropathy. *Brain*. 2021;144:1542–1550.
- Auer-Grumbach M, Toegel S, Schabhüttl M, et al. Rare variants in MME, encoding metalloprotease neprilysin, are linked to late-onset autosomal-dominant axonal polyneuropathies. *Am J Hum Genet*. 2016;99:607–608.
- Skre H. The significance of “unspecific neuropathy” in hereditary ataxias and related disorders. *Clin Genet*. 1975;7:209–218.
- Tian X, Liang WC, Feng Y, et al. Expanding genotype/phenotype of neuromuscular diseases by comprehensive target capture/NGS. *Neurol Genet*. 2015;1:e14.
- Braathen GJ, Hoyer H, Busk OL, Tveten K, Skjelbred CF, Russell MB. Variants in the genes DCTN2, DNAH10, LRIG3, and MYO1A are associated with intermediate Charcot–Marie–Tooth disease in a Norwegian family. *Acta Neurol Scand*. 2016;134:67–75.
- Pareyson D, Marchesi C. Diagnosis, natural history, and management of Charcot–Marie–Tooth disease. *Lancet Neurol*. 2009;8:654–667.
- Kahle KT, Khanna AR, Alper SL, et al. K-Cl cotransporters, cell volume homeostasis, and neurological disease. *Trends Mol Med*. 2015;21:513–523.
- Larbrisseau A, Vanasse M, Brochu P, Jasmin G. The Andermann syndrome: Agenesis of the corpus callosum associated with mental retardation and progressive sensorimotor neuronopathy. *Can J Neurol Sci*. 1984;11:257–261.
- Al Shibli N, Al-Maawali A, Elmanzalawy A, et al. A novel splice-site variant in SLC12A6 causes Andermann syndrome without agenesis of the corpus callosum. *J Pediatr Genet*. 2020;9:293–295.
- Pacheva I, Todorov T, Halil Z, et al. First case of Roma ethnic origin with Andermann syndrome: A novel frameshift mutation in exon 20 of SLC12A6 gene. *Am J Med Genet A*. 2019;179:1020–1024.
- Uyanik G, Elcioglu N, Penzien J, et al. Novel truncating and missense mutations of the KCC3 gene associated with Andermann syndrome. *Neurology*. 2006;66:1044–1048.
- Bogdanova-Mihaylova P, McNamara P, Burton-Jones S, Murphy SM. Expanding the phenotype of SLC12A6-associated sensorimotor neuropathy. *BMJ Case Rep*. 2021;14:e244641.
- Kahle KT, Flores B, Bharucha-Goebel D, et al. Peripheral motor neuropathy is associated with defective kinase regulation of the KCC3 cotransporter. *Sci Signal*. 2016;9:ra77.
- Park J, Flores BR, Scherer K, et al. De novo variants in SLC12A6 cause sporadic early-onset progressive sensorimotor neuropathy. *J Med Genet*. 2020;57:283–288.
- Shi J, Zhao F, Pang X, et al. Whole-exome sequencing identifies a heterozygous mutation in SLC12A6 associated with hereditary sensory and motor neuropathy. *Neuromuscul Disord*. 2021;31:149–157.
- Dyck PJ, Turner DW, Davies JL, et al. Electronic case-report forms of symptoms and impairments of peripheral neuropathy. *Can J Neurol Sci*. 2002;29:258–266.
- Goransson LG, Mellgren SI, Lindal S, Omdal R. The effect of age and gender on epidermal nerve fiber density. *Neurology*. 2004;62:774–777.
- Pettersen EF, Goddard TD, Huang CC, et al. UCSF ChimeraX: Structure visualization for researchers, educators, and developers. *Protein Sci*. 2021;30:70–82.
- Delpire E, Gagnon KB, Ledford JJ, Wallace JM. Housing and husbandry of *Xenopus laevis* affect the quality of oocytes for heterologous expression studies. *J Am Assoc Lab Anim Sci*. 2011;50:46–53.
- Xie Y, Chang S, Zhao C, et al. Structures and an activation mechanism of human potassium-chloride cotransporters. *Sci Adv*. 2020;6:eabc5883.
- Richards S, Aziz N, Bale S, et al. Standards and guidelines for the interpretation of australian sequence variants: A joint consensus recommendation of the American College of Medical Genetics and Genomics and the Association for Molecular Pathology. *Genetic Med*. 2015;17:405–424.
- Ellard S, Baple EL, Callaway A, et al. ACGS Best Practice Guidelines for Variant Classification in Rare Disease. Accessed 4 February 2020. <https://www.acgs.uk.com/media/11631/uk-practice-guidelines-for-variant-classification-v4-01-2020.pdf>
- Kingdom R, Wright C. Incomplete penetrance and variable expressivity: From clinical studies to population cohorts. *Front Genet*. 2022;13:920390.
- Howard HC, Mount DB, Rochefort D, et al. The K-Cl cotransporter KCC3 is mutant in a severe peripheral neuropathy associated with agenesis of the corpus callosum. *Nat Genet*. 2002;32:384–392.
- Pakdaman Y, Berland S, Bustad H, et al. Genetic dominant variants in STUB1, segregating in families with SCA48, display in vitro functional impairments indistinctive from recessive variants associated with SCAR16. *Int J Mol Sci*. 2021;22:5870.
- De Michele G, Galatolo D, Barghigiani M, et al. Spinocerebellar ataxia type 48: Last but not least. *Neurol Sci*. 2020;41:2423–2432.
- Meyer-Schuman R, Antonellis A. Emerging mechanisms of aminoacyl-tRNA synthetase mutations in recessive and dominant human disease. *Hum Mol Genet*. 2017;26(R2):R114–R127.