

Capping carious exposures in adults: a RCT comparing calcium hydroxide and MTA

R. Kundzina, L. Stangvaltaite, H.M. Eriksen, E. Kerosuo

Department of Clinical Dentistry, Faculty of Health Sciences, UiT The Arctic University of Norway, Tromsø, Norway

Short title: Direct capping in adults

Correspondence: Rita Kundzina, Department of Clinical Dentistry, Faculty of Health Sciences, UiT The Arctic University of Norway, 9037 Tromsø, Norway.

E-mail: rita.kundzina@uit.no

Number of figures: 2

Number of tables: 1

Abstract

The aim of this multicenter randomized clinical trial was to compare the effectiveness of mineral trioxide aggregate (MTA) and conventional calcium hydroxide (CH) dressing as a direct pulp capping (DPC) material in adult molars with carious pulpal exposure. Eighty adult subjects met strict inclusion criteria (including a minimum of 18 years of age and a deep carious lesion in a molar) and were recruited to the study. Ten were subsequently excluded due to lack of pulpal exposure. The remaining seventy subjects were randomly allocated to two parallel arms: a MTA arm (n=33) and a CH arm (n=37). Follow-up was planned after 1 week and at 6, 12, 24, and 36 months. The primary outcome was the survival of the capped pulps and the secondary outcome was the postoperative pain. At 24 months, the cumulative survival rate was 80% for the MTA group and 46% for the CH group ($p < 0.05$, Kaplan-Meier survival analysis, log-rank test). There was no statistically significant association between the capping material and postoperative pain ($p > 0.05$). MTA appeared to be more effective than conventional CH dressing as a DPC material in molars with carious pulpal exposure in adult patients. No adverse effects were reported in either group (ClinicalTrials.gov NCT01224925).

Introduction

The goal of vital pulp therapy, including direct pulp capping (DPC) and partial pulpotomy (PP), is to preserve tooth vitality through hard tissue repair of the open exposure, thereby protecting the pulp from secondary harmful events (Hørsted-Bindslev and Bergenholtz, 2010). Many different materials have been advocated for use in DPC over the years (Hasselgren, 2008).

Calcium hydroxide (CH) is considered the gold standard material for DPC. It was introduced almost 100 years ago, and the first scientific reports showed CH to be superior to an inert material in regard to pulp healing after pulpal exposure (Hermann, 1930; Nyborg, 1955). Two case-series carried out among subjects aged under 16 years have shown excellent results for PP using CH after both traumatic (Cvek, 1978) and carious pulpal exposures (Mejare and Cvek, 1993). In both studies about half the teeth had a closed apex at baseline, but this had no effect on the success rate. In retrospective studies comprising subjects from all age groups, the 5-year success rate after DPC in carious exposures ranged from 37% to 82% (Hørsted et al., 1985; Barthel et al., 2000; Mente et al., 2010; Mente et al., 2014). The age of the patient had a clear effect, with a higher success rate in younger subjects, but results on whether molars survived better than anteriors were contradictory (Hørsted et al., 1985; Mente et al., 2014).

Mineral trioxide aggregate (MTA) was first introduced 2 decades ago as a material for repairing lateral perforations and for root-end fillings (Lee et al., 1993; Torabinejad et al., 1993). MTA was first tested in monkeys and showed better dentin bridge formation than CH when used as a pulp capping material (Pitt Ford et al., 1996). Good pulp response was also found when MTA was used on healthy pulps with mechanical exposures in human teeth (Nair et al., 2008; Accorinte et al., 2009; Eskandarizadeh et al., 2011).

MTA was first tested as a pulp capping material among children and adolescents; a study was performed in which PP using MTA was compared to PP using CH in carious exposures (Qudeimat et al., 2007). A success rate of over 90% was found in both the MTA and the CH groups after an average of 2.9 years of follow-up, although the majority of teeth had a closed apex at baseline.

In a retrospective study in a group of patients aged 10-70 years, the success rate of DPC using CH decreased with increasing follow-up, showing a success rate of only 13% after 10 years (Barthel et al., 2000). In a recent multicenter randomized clinical trial (RCT) limited to carious exposures in adults, Bjørndal et al. (2010) reported no significant difference between DPC and PP, both using CH, after 1 year of follow-up; the success rates were less than 35% for both procedures. This is in line with current recommendations, which list pulpectomy as the treatment of choice in cases of pulpal exposure in adults (European Society of Endodontology, 2006; Holland et al., 2009).

A case-series of adults (age range: 7-45 years) used MTA for DPC in carious exposures (Bogen et al., 2008). In that study, the probability of 5-year pulp survival was 95%, indicating a high success rate regardless of the patient's age. A retrospective study restricted to adults demonstrated a 1-year survival rate of 68% for teeth that underwent DPC using MTA (Miles et al., 2010). Two retrospective studies, in which subjects aged 7 to 78 years old were followed for between 1 and 10 years, DPC using MTA showed a higher survival rate (80%) than DPC using CH (60%) (Mente et al., 2010; Mente et al., 2014). Similar results were reported in a recent practice-based research network RCT, with DPC using MTA and CH showing success rates of 80.3% and 68.5%, respectively, after a median of 12 months of follow-up in permanent teeth with carious, traumatic, or mechanical exposure (Hilton et al., 2013).

Although the recent literature suggests that MTA performs better than CH for DPC in adults, no randomized prospective study has yet assessed the efficacy of MTA when used for

carious exposures in adult patients. Thus, we performed a multicenter RCT to compare the effectiveness of MTA and conventional CH dressing as a DPC material in adult molars with carious pulpal exposure.

Material and methods

This multicenter RCT had two parallel arms, and followed the CONSORT guidelines (www.consort-statement.org). Subjects were recruited from three public clinics in Northern Norway: Sandnessjøen, Alta, and the student clinic at UiT The Arctic University of Norway (UiT); and one private clinic in Klaipeda, Lithuania. Treatment was performed by six different dentists. Strict inclusion criteria were applied: age 18 to 55 years; 1st or 2nd permanent molar with a proximal carious lesion (primary or secondary caries); no history of pain, or presence of pain indicating reversible pulpitis at most; positive response to electric pulp testing or cold test; radiograph showing caries in the inner 1/3 of the dentin; closed apex; normal periapex (with no radiolucency or widening of the periodontal ligament space); attachment loss not exceeding 4 mm; non-contributory medical history (including pregnancy); and no use of medication (no antibiotics during last month). Only one pulp cap could be included per subject.

Uniform criteria for diagnosis and treatment were applied in all study clinics. During the treatment procedure the tooth was anesthetized, isolated with a rubber dam, and the caries was removed using x2.5 magnifying glasses. The cavity outline (class II) was cut down to the sound enamel using a high speed bur and water cooling. Using a round bur at low speed, carious dentin was then completely removed from the non-pulpal walls of the cavity, until the dentin was hard when checked with a sharp probe, and all cavity margins were inside the sound tooth structure. A caries detector dye (Kuraray, Medical Inc, Tokyo, Japan) was applied, and a hand excavator was used to remove caries from the pulpal wall until no or little dye staining was present. Bleeding was controlled within 10 minutes using cotton pellets soaked in buffered 0.5% NaOCl (Dakin's solution).

Exclusion criteria included lack of pulpal exposure after total removal of caries, and failure to control the bleeding in exposed pulp within 10 minutes.

Randomization was implemented centrally at the UiT using the envelope method, with block sizes 4-6-4-6, and with each study clinic acting as a separate allocation unit. Envelopes were sent to the study clinics in batches of 20. The envelope revealed the treatment group to which the patient was to be allocated (either CH or MTA) and was only opened after bleeding in the exposed pulp was successfully controlled. Patients were not informed of their allocation group.

In the CH group, a thin layer of commercial CH material (Dycal[®], Dentsply DeTrey GmbH, Konstanz, Germany) was applied to the pulpal exposure and left to set. In the MTA group, white ProRoot[®] MTA (Dentsply, Tulsa Dental, Tulsa, OK, USA) powder was mixed according to the manufacturer's instructions, and a 2 mm-thick layer was placed directly over the pulpal exposure and the surrounding dentin, leaving at least 2 mm of dentin and enamel available circumferentially for the bonded composite restoration. After placing the MTA, a flat, water moistened cotton pellet was placed directly over the material. The cavities then received a temporary filling, using Fuji IX glass ionomer cement (GC Corp, Tokyo, Japan). After 1 week, any postoperative pain was recorded; pulpal status was checked, and if there were no symptoms the cavity was permanently restored with whatever composite resin filling material was in use at the study clinic.

Clinical and radiological follow-up, including pulpal testing, was planned at 6, 12, 24, and 36 months. The primary outcome was the survival of capped pulps. Survival was defined as a non-symptomatic tooth that responded to sensitivity testing and did not have any periapical changes. The secondary outcome measure was postoperative pain 1 week after treatment.

The power calculation was based on the intention to show a 30% difference in success rates. The following parameters were used: (binomial scale): type 1 error: 5%; expected success

rate in the CH group: 55% (based on Barthel et al., 2000); minimal difference between success rates not to be overlooked: 30%; type 2 error: 5%. The calculations showed the need to have 64 subjects in each group. After adding 20% for eventual drop-outs, we planned to recruit 160 subjects in 1 year.

Kaplan-Meier survival analysis was used to study the survival of the capped pulps. The log-rank (Mantel-Cox chi-square) test was used to assess the statistical differences in the survival curves between groups. The Chi-square test was used to assess the association between the materials and preoperative and postoperative pain. Data were entered and analyzed using the statistical program package IBM SPSS statistics 21.0 (IBM, Somers, New York, NY, USA).

Ethical approval (2010/2112-4) was obtained on 14 September 2010 from the Regional Committee for Medical and Health Research Ethics. Participation in the study was voluntary, and written informed consent was obtained from all participants.

Results

Recruitment did not proceed at the expected pace, with a total of 80 subjects recruited as of February 2013. Thus, in order to ensure the feasibility of reporting the results in a reasonable timeframe, recruitment was terminated, although only half the desired number of subjects had been enrolled. Ten subjects were later excluded due to lack of pulpal exposure after total removal of caries, whereas no subject had to be excluded due to failure to control the bleeding. Consequently, 70 subjects were randomly allocated to either the CH group (n=37) or the MTA group (n=33). In this paper we present the interim results of the RCT from baseline to at least 24-month follow-up (Figure 1).

Almost half of the subjects (34/70) experienced preoperative pain at baseline; these subjects were equally distributed between the two material groups. Postoperative pain at 1 week was reported by only 18 of the 70 subjects (Table 1). Regardless of the preoperative pain, there were no statistically significant associations between the material and the postoperative pain,

although postoperative pain was observed slightly more often (10/33) in the MTA group than the CH group (8/37) (Table 1). No adverse effects were reported in either group.

Kaplan-Meier survival analyses showed a cumulative survival rate of pulps of 80% in the MTA group and 46% in the CH group. This difference was found to be statistically significant ($p < 0.05$) by the log-rank test (Figure 2).

Discussion

RCTs are regarded as the gold standard of clinical research and are at the top of the hierarchy of evidence-based medicine (Giannobile, 2015). The multicentric nature of the present study represents an effective approach to enroll patients in a short time (Bjørndal et al. 2010). Eight public dental clinics were initially invited to enroll patients into our study, but after 2 months only two were willing to continue enrollment. In order to ensure we could report the results in a reasonable time interval, we included two more clinics and expanded subject recruitment time to 3 years. Despite our efforts, only half of the number of subjects we planned for based on the power calculation could be recruited. However, this fact did not lead to type II error, since the results showed a statistically significant difference between the material groups, the limited number of subjects notwithstanding.

The validity of the study was secured by implementing strict inclusion criteria. It was essential to limit the age to a minimum of 18 years in order to reflect results in adults. It has been demonstrated that the success rates for both CH and MTA are age-dependent, and show very high success in adolescents (Qudeimat et al., 2007), but declining values in older subjects (Bjørndal et al., 2010; Mente et al., 2014). The prospective design of our RCT ensured our ability to include only subjects with carious exposures, which have been shown to have lower success rates than pulpal exposures of mechanic (iatrogenic) or traumatic origin (Mente et al., 2014).

For practical reasons, envelope randomization was chosen instead of centralized on-line allocation. Although each clinic had had its own set of envelopes, small block sizes ensured the balance in sample size across the groups over time.

In order to limit this RCT study to two arms only, we had to choose between the DPC and PP method. Good results have been shown for DPC with MTA in adults (Bogen et al., 2008), whereas PP has been used mostly in adolescents (Qudeimat et al., 2007). Therefore we chose DPC, which is in line with the results of Bjørndal et al. (2010), who did not find any significant difference between PP and DPC when CH was used as a dressing material in adult teeth.

Dycal was chosen as the CH material as good clinical results have been reported for this material when used for DPC, including in adult patients (Hørsted et al., 1985).

MTA was chosen as it has been shown to perform better than Dycal CH in histological studies (Nair et al. 2008, Eskandarizadeh et al., 2011). The study by Eskandarizadeh et al. assessed calcified bridge thickness and pulp inflammatory response in 90 healthy human premolars, but failed to show any significant difference between grey and white MTA. There are no studies comparing white and grey MTA in DPC in permanent teeth, but they performed equally well when used in pulpotomies for primary teeth, although the bridge formation was more pronounced with grey MTA (Cardoso-Silva et al, 2010).

Despite the written, uniform treatment criteria that were explained to the dentists performing the treatment before commencing the study, we learned that the protocol was violated in one of the study clinics; that clinic did not use rubber dam and magnification in all cases. However, this did not negatively influence the outcome, as the overall success rate in that particular clinic was above the average observed in the other study clinics. In four subjects, occlusal cavities were included, but as these four subjects were equally distributed between the MTA and CH groups, they had no bearing to the comparison of the materials. Treatment in our

study was performed by general dental practitioners who did not have specialist equipment (including operating microscope), and all patients were treated as part of routine practice.

After a 2-3 years follow-up, the estimated survival rate of the pulps among subjects who underwent DPC using CH was 46%. This is in contrast to another recent multicenter RCT (Bjørndal et al., 2010), in which the success rate for DPC using CH dropped after 1 year to 32%. As in our study, also the study by Bjørndal et al. was limited to adults only, and used Dycal as the DPC material. It would be tempting to suggest that a plausible explanation for the difference between this study and ours was the use of a rubber dam. Indeed, in our study, a rubber dam was placed before starting any caries removal, whereas in the study by Bjørndal et al. it was placed only after the exposure had happened. However, this explanation is undermined by the fact that one of our study clinics violated the protocol by using no rubber dams at all, yet it had the best results in our study. On the other hand, we found many more failures with CH in comparison to the retrospective study by Mente et al. (2014), in which the estimated survival rate for carious exposures after 2-4 years was 57%. This difference may be explained by the difference in the age distribution, as no strict age criteria were applied in the aforementioned retrospective study. The survival rate we observed for CH was most in line with that found by Hilton et al. (2013), who reported an increase in the failure rate from 30% after 2 years, to more than 50% in the following 6 months.

After 2-3 years of follow-up we found that pulps treated with DCP using MTA had a statistically significantly better survival than those treated with DCP using CH (80% vs. 46%, respectively) (Fig. 2). For MTA, this finding is in accordance with the results of a recent study (Hilton et al., 2013), in which MTA showed a 80.3% probability of success at 2 years. They also found MTA to perform better than CH, but the difference was not statistically significant. Moreover, as their results were stratified neither according to the age of the patient nor by type

of tooth (molar/premolar/ incisor) or origin of the exposure (13.7% non-carious), the evidence is limited when it comes to choice of material over carious exposures in adult molars.

Our findings are also well in line with the results of Mente et al. (2014), who showed a success rate for carious exposures capped with MTA of 80% after 2 years, but the success rate for carious exposures in adults may have been slightly lower in their study, as the origin of exposure and age were not controlled for simultaneously.

There were no statistically significant differences in postoperative pain between the material groups. This finding is in accordance with the study by Iwamoto et al. (2006), where capping healthy pulps with MTA and CH (Dycal) yielded no difference in pain experience, although a histological study showed less inflammation in human teeth capped with MTA in comparison to CH (Aeinehchi et al., 2003). Both materials are chemicals, and after application they affect the pulp and cause inflammation, which is part of the healing process (Cooper et al., 2014).

To our knowledge, this is the first RCT in adults only, comparing MTA and CH in DPC, and restricted to carious exposures in molars. In order to recommend DPC as a routine treatment, the estimated 2-year survival rate of MTA (80%) must be compared with the long-term outcome of pulpectomy followed by endodontic treatment. It is well established that vital teeth (or teeth without a periapical lesion) have a better endodontic prognosis than teeth with apical periodontitis (Kerekes and Tronstad, 1979; Ng et al., 2008). This fact underlines the necessity to make decisions regarding pulpectomy immediately, as the prognosis for the tooth is inferior if root canal treatment is performed only after failed DPC. In systematic reviews the prognosis for primary endodontic treatment varies significantly and survival rates are higher than success rates, although the latter is usually measured in endodontic studies (Kojima et al., 2004; Ng et al., 2007; Ng et al., 2010; Setzer and Kim, 2014). One argument in favor of DPC using MTA is that a general dental practitioner is more likely to perform this procedure very

well, as compared to an endodontic procedure, which is considered more complicated. Our results may challenge established treatment guidelines in endodontics by preferring DPC with MTA to pulpectomy in adult patients, particularly if high-quality endodontic services are not available. In addition, CH may no longer be the gold standard for DPC, and its use as a dressing material among adults may be debatable.

In conclusion, MTA is more effective than conventional CH dressing as a DPC material in molars with carious pulpal exposure in adult patients.

Acknowledgements

This study was supported by UiT The Arctic University of Norway and Troms County. The authors acknowledge the clinics in Alta, Klaipeda, Sandnessjoen, and the student clinic at UiT The Arctic University of Norway for implementing the study. Our thanks also go to Hannu Vähänikkilä, MSc, for performing the statistical analyses.

The authors declare no potential conflicts of interest with respect to the authorship and/or publication of this article.

References

- Accorinte ML, Loguercio AD, Reis A, Bauer JR, Grande RH, Murata SS *et al.* (2009). Evaluation of two mineral trioxide aggregate compounds as pulp-capping agents in human teeth. *Int Endod J* 42(2):122-128.
- Aeinehchi M, Eslami B, Ghanbariha M, Saffar AS (2003). Mineral trioxide aggregate (MTA) and calcium hydroxide as pulp-capping agents in human teeth: a preliminary report. *Int Endod J* 36(3):225-231.
- Barthel CR, Rosenkranz B, Leuenberg A, Roulet JF (2000). Pulp capping of carious exposures: treatment outcome after 5 and 10 years: a retrospective study. *J Endod* 26(9):525-528.
- Bjørndal L, Reit C, Bruun G, Markvart M, Kjældgaard M, Nasman P *et al.* (2010). Treatment of deep caries lesions in adults: randomized clinical trials comparing stepwise vs. direct complete excavation, and direct pulp capping vs. partial pulpotomy. *Eur J Oral Sci* 118(3):290-297.
- Bogen G, Kim JS, Bakland LK (2008). Direct pulp capping with mineral trioxide aggregate: an observational study. *J Am Dent Assoc* 139(3):305-315.
- Cooper PR, Holder MJ, Smith AJ (2014). Inflammation and regeneration in the dentin-pulp complex: a double-edged sword. *J Endod* 40(4 Suppl):S46-51.
- Cvek M (1978). A clinical report on partial pulpotomy and capping with calcium hydroxide in permanent incisors with complicated crown fracture. *J Endod* 4(8):232-237.
- Eskandarizadeh A, Shahpasandzadeh MH, Shahpasandzadeh M, Torabi M, Parirokh M (2011). A comparative study on dental pulp response to calcium hydroxide, white and grey mineral trioxide aggregate as pulp capping agents. *Journal of conservative dentistry : JCD* 14(4):351-355.
- European Society of Endodontology (2006). Quality guidelines for endodontic treatment: consensus report of the European Society of Endodontology. *Int Endod J* 39(12):921-930.
- Giannobile WV (2015). Improving clinical trials in dentistry. *J Dent Res* 94(3 Suppl):6s-7s.
- Hasselgren G (2008). Treatment of the exposed pulp-dentin complex. In: Essential endodontology: prevention and treatment of apical periodontitis. D Ørstavik and T Pitt Ford editors. Oxford: Blackwell Munksgaard, pp. 303.

Hilton TJ, Ferracane JL, Mancl L, NWP (2013). Comparison of CaOH with MTA for direct pulp capping: a PBRN randomized clinical trial. *J Dent Res* 92(7 suppl):S16-22.

Holland GR, Trowbridge OH, Rafter M (2009). Protecting the pulp, preserving the apex. In: Endodontics principles and practice. M Torabinejad and RE Walton editors. Missouri, USA: Saunders Elsevier.

Hørsted-Bindslev P, Bergenholtz G (2010). Treatment of vital pulp conditions. In: Textbook of endodontology. G Bergenholtz, P Hørsted-Bindslev and C Reit editors. UK: Wiley-Blackwell.

Hørsted P, Sandergaard B, Thylstrup A, El Attar K, Fejerskov O (1985). A retrospective study of direct pulp capping with calcium hydroxide compounds. *Endod Dent Traumatol* 1(1):29-34.

Iwamoto CE, Adachi E, Pameijer CH, Barnes D, Romberg EE, Jefferies S (2006). Clinical and histological evaluation of white ProRoot MTA in direct pulp capping. *Am J Dent* 19(2):85-90.

Kerekes K, Tronstad L (1979). Long-term results of endodontic treatment performed with a standardized technique. *J Endod* 5(3):83-90.

Kojima K, Inamoto K, Nagamatsu K, Hara A, Nakata K, Morita I *et al.* (2004). Success rate of endodontic treatment of teeth with vital and nonvital pulps. A meta-analysis. *Oral Surg Oral Med Oral Pathol Oral Radiol Endod* 97(1):95-99.

Lee SJ, Monsef M, Torabinejad M (1993). Sealing ability of a mineral trioxide aggregate for repair of lateral root perforations. *J Endod* 19(11):541-544.

Mejåre I, Cvek M (1993). Partial pulpotomy in young permanent teeth with deep carious lesions. *Endod Dent Traumatol* 9(6):238-242.

Mente J, Geletneky B, Ohle M, Koch MJ, Friedrich Ding PG, Wolff D *et al.* (2010). Mineral Trioxide Aggregate or Calcium Hydroxide Direct Pulp Capping: An Analysis of the Clinical Treatment Outcome. *Journal of Endodontics* 36(5):806-813.

Mente J, Hufnagel S, Leo M, Michel A, Gehrig H, Panagidis D *et al.* (2014). Treatment outcome of mineral trioxide aggregate or calcium hydroxide direct pulp capping: long-term results. *J Endod* 40(11):1746-1751.

Miles JP, Gluskin AH, Chambers D, Peters OA (2010). Pulp capping with mineral trioxide aggregate (MTA): a retrospective analysis of carious pulp exposures treated by undergraduate dental students. *Oper Dent* 35(1):20-28.

Nair PNR, Duncan HF, Pitt Ford TR, Luder HU (2008). Histological, ultrastructural and quantitative investigations on the response of healthy human pulps to experimental capping with mineral trioxide aggregate: a randomized controlled trial. *Int Endod J* 41(2):128-150.

Ng YL, Mann V, Rahbaran S, Lewsey J, Gulabivala K (2007). Outcome of primary root canal treatment: systematic review of the literature – Part 1. Effects of study characteristics on probability of success. *Int Endod J* 40(12):921-939.

Ng YL, Mann V, Rahbaran S, Lewsey J, Gulabivala K (2008). Outcome of primary root canal treatment: systematic review of the literature -- Part 2. Influence of clinical factors. *Int Endod J* 41(1):6-31.

Ng YL, Mann V, Gulabivala K (2010). Tooth survival following non-surgical root canal treatment: a systematic review of the literature. *Int Endod J* 43(3):171-189.

Pitt Ford TR, Torabinejad M, Abedi HR, Bakland LK, Kariyawasam SP (1996). Using mineral trioxide aggregate as a pulp-capping material. *J Am Dent Assoc* 127(10):1491-1494.

Qudeimat MA, Barrieshi-Nusair KM, Owais AI (2007). Calcium hydroxide vs mineral trioxide aggregates for partial pulpotomy of permanent molars with deep caries. *Eur Arch Paediatr Dent* 8(2):99-104.

Setzer FC, Kim S (2014). Comparison of long-term survival of implants and endodontically treated teeth. *J Dent Res* 93(1):19-26.

Torabinejad M, Watson TF, Pitt Ford TR (1993). Sealing ability of a mineral trioxide aggregate when used as a root end filling material. *J Endod* 19(12):591-595.

Legend to the figures

Figure 1. Flow chart of the 80 eligible subjects, when all cases had been followed-up at least 24 months.

Figure 2. Kaplan-Meier analysis of survival of pulps. The estimated cumulative proportion surviving was 0.463 for CH (N=37) and 0.800 for MTA (N=33).

Table 1. The frequency of postoperative pain in relation to preoperative pain and the capping material used. N=70.

Capping material	Pre-operative pain ²	Postoperative pain ¹				Total
		No	Mild, during first 3 days only	Mild, occasionally during entire week	Severe pain at any point	
CH	No	15	4	0	0	19
	Yes	14	3	0	1	18
Sub total		29	7	0	1	37
MTA	No	15	1	1	0	17
	Yes	8	4	2	2	16
Subtotal		23	5	3	2	33
Grand total		52	12	3	3	70

¹Pain at any point during the first week.

²Pain at any point during one month prior to the procedure.

Statistical analysis with Chi-square test:

Capping material vs. Preoperative pain; $p>0.05$

Group with preoperative pain: capping material vs. postoperative pain; $p>0.05$

Group without preoperative pain: capping material vs. postoperative pain; $p>0.05$

Figure 1.

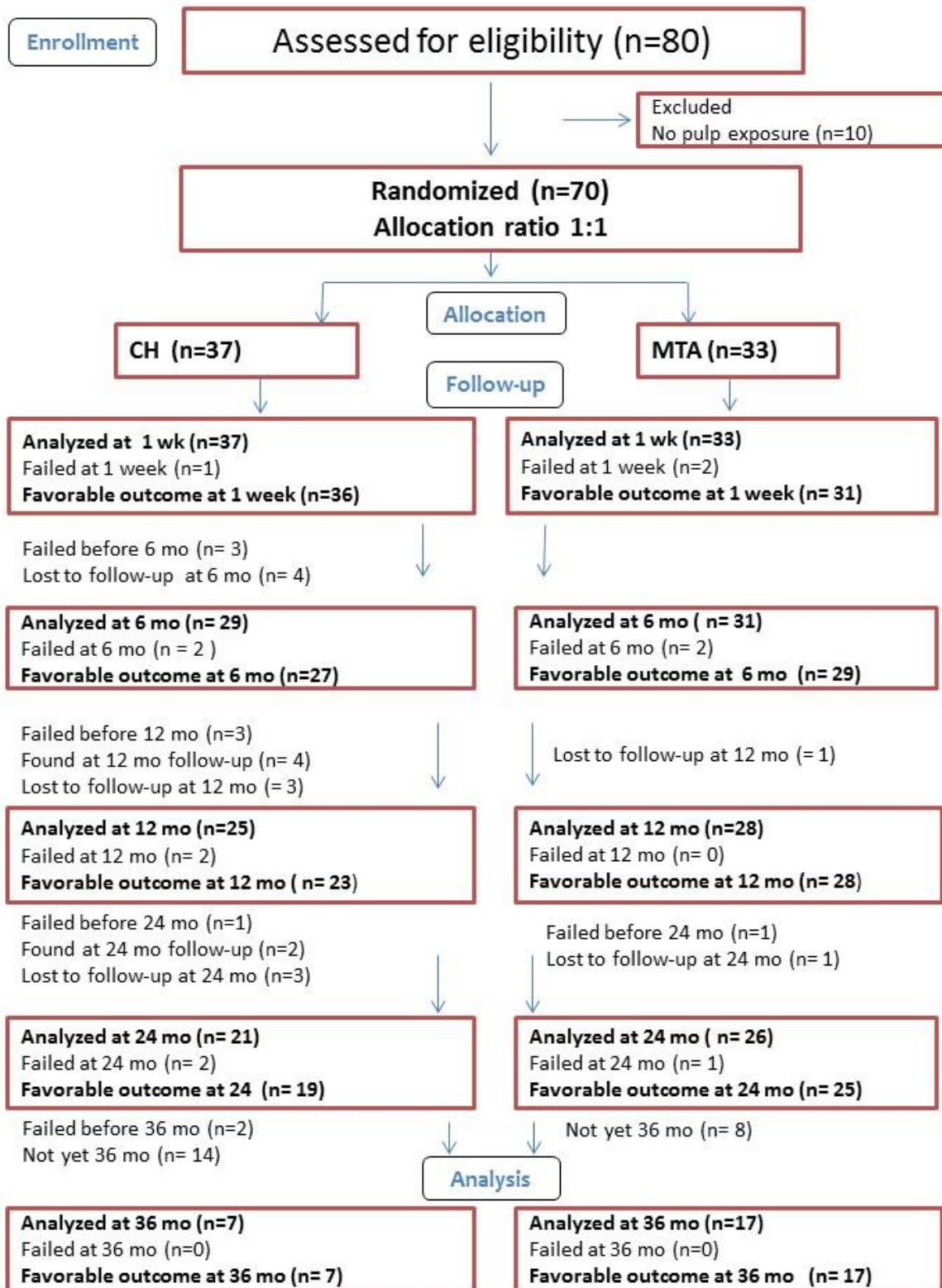


Figure 2.

