

CASE REPORT

Mild phenotype in an adult male with X-linked adrenoleukodystrophy – case report

Morten A. Horn^{1,2}, Karin B. M. Mikaelson³, Sacha Ferdinandusse⁴, Ellen Jørum^{1,2}, Svein I. Mellgren^{5,6}, Lars Retterstøl⁷, Ronald J. A. Wanders⁴ & Chantal M. E. Tallaksen^{1,2}

¹Department of Neurology, Oslo University Hospital, PO Box 4956 Nydalen, Oslo N-0424, Norway

²Department of Neurology, Faculty of Medicine, University of Oslo, PO Box 1078 Blindern, Oslo N-0316, Norway

³Department of Neurology, Molde Hospital HF, Parkveien 84, Molde N-6407, Norway

⁴Laboratory Genetic Metabolic Diseases, Department of Clinical Chemistry, Academic Medical Centre, Meibergdreef 9, Amsterdam 1105 AZ, The Netherlands

⁵Department of Neurology, University Hospital of Northern Norway, Tromsø N-9038, Norway

⁶Department of Clinical Medicine, UiT the Arctic University of Norway, PO Box 6050 Langnes, N-9037 Tromsø, Norway

⁷Department of Medical Genetics, Oslo University Hospital, N-0424 Oslo, Norway

Correspondence

Morten Andreas Horn, Department of Neurology, Oslo University Hospital, PO Box 4956 Nydalen, N-0424 Oslo, Norway.
Tel: +4791118868; Fax: +4722118801;
E-mail: hormor@ous-hf.no

Funding Information

No sources of funding were declared for this study.

Received: 4 June 2015; Revised: 17 September 2015; Accepted: 29 September 2015

Clinical Case Reports 2016; 4(2): 177–181

doi: 10.1002/ccr3.434

Introduction

X-linked adrenoleukodystrophy (X-ALD) [1] was initially known as a usually fatal progressive cerebral leukodystrophy of childhood, affecting boys. Later on, it was recognized that this childhood form occurs in only about one-third of males (hemizygotes). However, males who survive into adulthood develop a picture of adrenal and testicular insufficiency, myelopathy and peripheral neuropathy known as adrenomyeloneuropathy (AMN). Onset of AMN in males is usually in the 3rd or 4th decade [1]. Recent research [2–4] has shown that a large proportion of AMN males develop cerebral demyelination during adulthood. Furthermore, a phenotype characterized by myeloneuropathy is found in most females (heterozygotes) beyond the age of 50–60 [3, 5, 6]. Therefore, a current view of X-ALD is that a more severe course, with age-dependent penetrance, is seen in both male and female subjects.

Key Clinical Message

X-linked adrenoleukodystrophy may present with a deceptively mild phenotype, even in adult males. Tight collaboration between clinicians, geneticists, biochemists, and other specialists is increasingly required for clarification of diagnosis in cases with atypical presentation.

Keywords

Adrenomyeloneuropathy, leukodystrophy, myelopathy, Parkinson's disease, phenotype, X-linked adrenoleukodystrophy

A few elderly males with mild symptoms have been reported [7–10], but descriptions detailing symptoms and features in this subset of patients are lacking. The existence of such phenotypes is important, both for the counseling of young males diagnosed with X-ALD on the basis of genetic studies, and for the further investigation of X-ALD kindreds searching for affected males who may form a link to other affected branches of the pedigree.

Case Report

A 61-year-old male patient of Norwegian ethnicity was evaluated for Parkinson's disease, when clinical examination disclosed subtle signs of myelopathy. Elevated levels of very long-chain fatty acids (VLCFAs) had raised the possibility of X-ALD as a differential diagnosis. A genetic variant of uncertain significance [11] previously not

reported in the X-ALD database (www.x-ald.nl) had been found in the *ABCD1* gene.

The patient had first been investigated at age 48 for frequent fasciculations in the legs. Neurophysiologic studies at that time suggested a slight sensorimotor peripheral neuropathy. At age 51, Babinski signs were demonstrated bilaterally, without any other signs of pyramidal tract dysfunction. However, during the subsequent years, he developed a slight, but definite, tetraspasticity and symmetrical hyperreflexia, with subjective symptoms of muscle stiffness, gait difficulties, and unsteadiness. Yet, his motor function was still good; he retained the ability to run and take strenuous hikes in the mountains.

From age 57, he developed asymmetric bradykinesia and rigidity, a clinical picture typical of Parkinson's disease. Multisystem atrophy of the Parkinsonian type could be suspected; however, there was an excellent response to levodopa therapy. The patient's function returned to near normal levels: He was fully ambulatory without aids, played basketball matches and worked full time in an office.

At the time of the study, Spastic Paraplegia Rating Scale [12] score was 4/52 (0/1/0/0/0/0/2/1/0/0/0/0/0) points. The Expanded Disability Status Scale [13] score was 3.0 (normal ambulation, FS score 3 for sensory functions, FS score 1 for pyramidal functions, bladder/bowel functions and spasticity, others 0).

The patient's family history was negative for X-ALD, even when searching for minor details suggesting mild myelopathy or Addisonism in his mother or other ancestors. His father had typical levodopa-responsive Parkinson's disease, negative for *LRRK2* mutations. The patient's brother died at age 44, without any history

indicating myelopathy or Addisonism. The patient's only daughter was clinically healthy at age 32.

Due to the scarcity of symptoms typical for X-ALD, the lack of family history and the absence of evidence that the genetic variant was pathogenic, we were uncertain whether the patient should be classified as having X-ALD. He therefore underwent further investigations.

Investigations

The patient underwent thorough clinical, paraclinical, (Table 1) and biochemical (Tables 2 and 3) work-up. MRI of brain and spinal cord showed no signs of demyelination. Standard neurophysiologic studies demonstrated a progressive, moderate sensorimotor polyneuropathy of the lower extremities, with predominantly axonal changes. Neurophysiologic small nerve fiber studies were mostly normal; however, skin biopsy [14] revealed a loss of intraepidermal small nerve fibers.

The patient had no symptoms or clinical signs suggesting primary adrenal or testicular insufficiency, except scanty scalp hair, also seen in his father. Endocrinologic measurements in blood were normal, including ACTH stimulation test to rule out subclinical adrenal insufficiency. VLCFA measurements and enzymatic studies were performed in a diagnostic setting in cultured fibroblasts grown from a skin biopsy taken at age 60; the findings were consistent with X-ALD.

Individual exons with flanking intron sequences of the *ABCD1* gene were amplified from DNA extracted from EDTA-containing blood. The sequencing products were run on a Genetic Analyzer 3730 (Applied Biosystems, Foster City, California, USA) and analyzed using Secscape

Table 1. Paraclinical studies in adult male patient with mild X-ALD phenotype.

Modality	Age at examination	Results
CSF studies	–	Normal cell count and protein level, no OCBs
MRI ¹ of brain and spinal cord	61	No sign of demyelination or damage to the long tracts. Visual impression of slender thoracic cord. Loes score 0
Brain SPECT using DaTscan	58	Asymmetrically reduced signal intensity in the basal ganglia, more pronounced on the right side, consistent with PD
EMG and NCV studies	61	Moderate sensorimotor peripheral neuropathy in lower extremities, predominantly axonal changes. Chronic neurogenic changes on EMG
SNF studies	61	Galvanic skin response normal in hands and feet. Normal heart rate variability with heavy breathing. Elevated threshold for heat sensitivity on left foot, otherwise normal thermal sensitivities
IENFD measurements	61	2.1/mm (normal values (age and gender adjusted): ≥ 4.9)

CSF, cerebrospinal fluid; OCBs, oligoclonal bands; SPECT, single photon emission computed tomography; DaTscan, ioflupane (¹²³I); PD, Parkinson's disease; EMG, electromyography; NCVs, nerve conduction velocities; SNF, small nerve fiber; IENFD, intraepidermal nerve fiber density. Loes score is a grading scale for extent and severity of demyelinating lesions in MRI imaging of the brain in X-linked adrenoleukodystrophy, range 0 (normal) to 34 (most severe).

¹The following MRI sequences were performed: Brain: T1, T1 with MRI contrast medium (Gadolinium), T2, FLAIR and diffusion-weighted imaging (DWI) sequences. Spinal cord: T1, T2, short tau inversion recovery (STIR) and DWI sequences.

Table 2. Laboratory studies in adult male patient with mild X-ALD phenotype.

Assay	Results	Unit	Reference values
Endocrinologic assays			
s-cortisol	517	nmol/L	138–690
p-ACTH	6.4	pmol/L	<10.2
ACTH stimulation test			See legend
s-cortisol pre-stimulation	521	nmol/L	
s-cortisol at 30 min	802	nmol/L	
s-cortisol at 60 min	849	nmol/L	
s-testosterone	12.4	nmol/L	8.0–35.0
s-SHBG	46	nmol/L	15–90
Immunological assays			
Anti-ENA ELISA	Negative	–	Negative
s-VGKC autoantibodies	<85	pmol/L	<85
21OH-autoantibodies	<0.03	Arbitrary index	<0.10
VLCFA studies			
In serum			
C22:0	17.7	mg/L	10.1–24.5
C24:0	30.6	mg/L	7.9–22.8
C26:0	1.02	mg/L	<0.3
C24:0/C22:0 ratio	1.73	–	0.81–0.96
C26:0/C22:0 ratio	0.058	–	0.010–0.018
In cultured fibroblasts			
C22:0	2.13	μmol/g protein	3.84–10.20
C24:0	8.56	μmol/g protein	7.66–17.66
C26:0	1.05	μmol/g protein	0.18–0.38
C24:0/C22:0 ratio	4.02	–	1.55–2.30
C26:0/C22:0 ratio	0.50	–	0.03–0.07

X-ALD, X-linked adrenoleukodystrophy; s-, serum; p-, plasma; ACTH, adrenocorticotrophic hormone; SHBG, sex hormone-binding globulin; ENA, extractable nuclear antigens (includes anti-dsDNA, anti-SmD, anti-RNP, anti-SSA/Ro52, anti-SSA/Ro60, anti-SSB/La, anti-CENP-B, anti-Scl70, anti-Jo-1, anti-Fibrillarin, anti-Mi-2, anti-PCNA, anti-Ribosomal P, anti-RNA Pol III and anti-PM-Scl100); ELISA, enzyme-linked immunosorbent assay; VGKC, voltage-gated potassium channels; 21OH, 21-hydroxylase; VLCFA, very long-chain fatty acids; C22:0, C24:0 and C26:0 are saturated unbranched fatty acids with 22, 24 and 26 carbon atoms, respectively. The rapid ACTH stimulation test is performed by intravenous injection of 250 μg Synacthen® (ACTH), with measurements of s-cortisol at 0, 30 and 60 min. A normal response is poststimulation values of ≥500 nmol/L, and a rise from baseline of ≥200 nmol/L.

version 2.6 software (Applied Biosystems). The sequence disclosed a previously unreported missense variant of uncertain significance in exon 3, c.1205T>A (p.Ile402Asn) using the following primers for sequencing exon 3: Forward 5'-ATTTGCAGAAGAGCCTCGCC-3' and Reverse 5'-TGCAGGGAGAGAAGCATGGC-3'. The variant was not found in exomes from 61,846 unrelated individuals in the Exome Aggregation Consortium Cambridge, MA (URL: <http://exac.broadinstitute.org>) October 2014 (coordinates: X:153001689T/A). Another missense variant in the *ABCD1* gene (c.1202G>A, p.Arg401Gln) causing a shift in the neighboring position in the ALDP protein, is

Table 3. Enzymatic studies in cultured fibroblasts from adult male patient with mild X-ALD phenotype.

Assay	Results	Unit	Reference values
Phytanic acid α-oxidation activity	33	pmol/(h.mg protein)	28–95
Peroxisomal β-oxidation activity with C26:0 as a substrate	243	pmol/(h.mg protein)	800–2040
Peroxisomal β-oxidation activity with pristanic acid as a substrate	902	pmol/(h.mg protein)	790–1690

X-ALD, X-linked adrenoleukodystrophy.

reported as pathogenic (www.x-ald.nl). Prediction tools indicated that the variant was likely to be pathogenic (SIFT: Deleterious, Mutation Taster: Disease-causing). MLPA for detection of larger deletions and duplications (MLPA kit P049; MRC-Holland, Amsterdam, The Netherlands) was negative.

The *ABCD1* variant was retrieved in the patient's healthy daughter. She was found to have elevated VLCFA levels, consistent with the heterozygous presymptomatic state of X-ALD.

To study the consequences of the mutation, enzymatic studies in cultured fibroblasts were performed, showing elevated C26:0 levels and impaired peroxisomal β-oxidation using C26:0 as a substrate (Table 3). Immunofluorescence studies of cultured fibroblasts (Fig. 1) showed normal staining using antibodies raised against catalase, a peroxisomal matrix enzyme. Staining using monoclonal antibodies raised against the ALD protein (ALDP) showed a mosaic pattern with most cells without ALDP staining, but also cells with ALDP staining.

Discussion

This patient presented a clinical picture of myelopathy and peripheral neuropathy, consistent with AMN, but much milder than expected in AMN males at the age of 61. The biochemical findings in blood and cultured fibroblasts, and the retrieval of the patient's mutation in his daughter (who also had elevated VLCFAs), confirmed this as a mild, but definite, X-ALD phenotype. In the classification of Norwegian X-ALD subjects presented previously, he would have been put in the "SIGNS" category [3].

The mildness of the myelopathy, the absence of endocrine dysfunction (adrenal failure being a hallmark of X-ALD), and the predominance of Parkinsonism in the clinical picture, contributed to a delay in the diagnosis of X-ALD. Failure to detect X-ALD may hamper the identification of affected relatives, thereby missing opportunities for early detection of Addisonism in boys and follow-up of

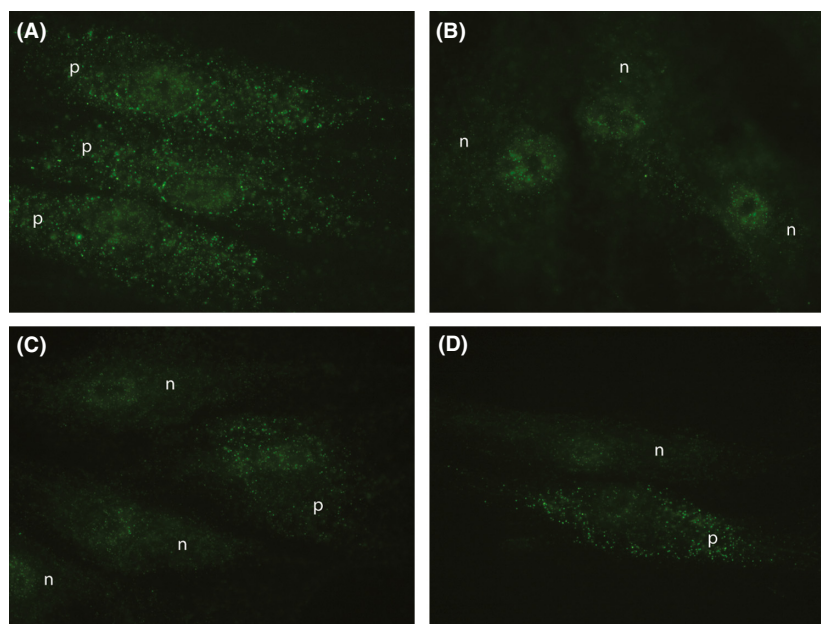


Figure 1. Immunofluorescence microscopy analyses with monoclonal antibodies against adrenoleukodystrophy protein (ALDP) (EUROMEDEX, ALD-ID6-AS). ALDP immunofluorescence microscopy analyses show the presence of ALDP in the peroxisomal membrane in control fibroblasts (punctate pattern, positive) (A), the absence of ALDP in the peroxisomal membrane in fibroblasts from an X-ALD patient without ALDP expression (negative) (B), and a mosaic pattern with most cells without peroxisomal ALDP staining (negative), but some cells with peroxisomal ALDP staining (positive) in the patient (C and D). p, positive; n, negative.

boys in order to provide hematopoietic stem cell transplantation in case of cerebral leukodystrophy [15] and genetic counseling.

We are not aware that Parkinsonism has been reported as a phenotype of *ABCD1* mutations. Multisystem atrophy of the striatonigral form (in which a combination of Parkinsonism and pyramidal signs may be seen) was unlikely, given the excellent response to levodopa therapy. The most likely interpretation is that Parkinsonian features in this patient were unrelated to the *ABCD1* mutation.

We remain uncertain as to how to classify the long-standing symptom of fasciculations in the legs. The patient did not fit with criteria for the cramps-fasciculation syndrome or amyotrophic lateral sclerosis. Fasciculations may be seen in many hereditary neurological disorders, and may remain an unspecific finding [16]. It is possible that his symptoms might be due to instability of peripheral motor nerves due to his slowly developing AMN, yet this remains speculative.

The lack of genotype–phenotype correlations in X-ALD has been emphasized in the literature [17]. However, differentiation must be made between two aspects of phenotype evolution in X-ALD: one aspect is whether or not the male patient will develop cerebral ALD, in childhood or later on [2, 4]. Another aspect is the age at onset and rate of progression of AMN. These elements are not necessarily linked, as the cerebral leukodystrophy of X-ALD

is partly inflammatory in nature, and possibly related to external factors like head trauma [18], whereas the myelopathy is due to slow axonal degeneration [19]. Unknown genetic factors may be partly responsible for the mild AMN phenotype seen in this patient. However, family counseling must for the time being assume that his descendants run the same risk as usual of developing symptomatic myelopathy (in females) and cerebral leukodystrophy (in boys).

Our understanding of the natural history of X-ALD is currently evolving [19]. The slowly progressive myeloneuropathy could be the basic phenotype, affecting most or all genetically affected subjects, whereas the devastating cerebral demyelination may be an epiphenomenon, possibly triggered in part by external factors. In this regard, factors determining the severity of the myeloneuropathy, in terms of age at onset and rate of progression, may be important for our understanding of the disease. Patients with very mild or very severe phenotypes may provide important clues.

About 700 unique mutations have been described in the *ABCD1* gene (www.x-ald.nl). Most families have their own, “private” mutation [17]. Furthermore, *de novo* mutations may be more common than previously reported [3]. Therefore, new patients will frequently present with a negative family history, and with a mutation of undecided pathogenicity. In this patient, the clinical

picture was atypical for X-ALD, and the *ABCD1* mutation was a previously unreported variant of uncertain significance. This is a situation clinicians may encounter more often, as sequencing of genes, exomes, and genomes becomes more widespread. Such a variant should not be used as the sole basis of clinical decision making; as illustrated by this report, thorough studies may be necessary to verify that the mutation is pathogenic. In this patient, the rare disorder of X-ALD was masked by the more common Parkinson's disease, a reminder that rare disorders may occur together with more common ones.

Acknowledgments

We thank the patient for contributing to the study. We thank Bård Nedregaard (Oslo University Hospital) for his help in the MRI evaluation of the patient, and Petra A.W. Mooyer (Academic Medical Centre, Amsterdam) for her help with the fibroblast studies. Furthermore, we thank Live Horn and Inge-Petter Kleggetveit (both Oslo University Hospital), and Edel Olsen (UiT The Arctic University of Norway) for assistance with the skin biopsy for intraepidermal nerve fiber density (IENFD) measurements, and Eli Ormerod (Oslo University Hospital) for assistance with fibroblast cultures. Thanks to Berit Torjusen and Thor Haug (Molde Hospital) for assistance with the ACTH stimulation test.

Conflicts of Interest

None declared.

References

- Engelen, M., S. Kemp, M. de Visser, et al. 2012. X-linked adrenoleukodystrophy (X-ALD): clinical presentation and guidelines for diagnosis, follow-up and management. *Orphanet J. Rare Dis.* 7:51.
- van Geel, B. M., L. Bezman, D. J. Loes, H. W. Moser, and G. V. Raymond. 2001. Evolution of phenotypes in adult male patients with X-linked adrenoleukodystrophy. *Ann. Neurol.* 49:186–194.
- Horn, M. A., L. Retterstol, M. Abdelnoor, O. H. Skjeldal, and C. M. Tallaksen. 2013. Adrenoleukodystrophy in Norway: high rate of de novo mutations and age-dependent penetrance. *Pediatr. Neurol.* 48:212–219.
- de Beer, M., M. Engelen, and B. M. van Geel. 2014. Frequent occurrence of cerebral demyelination in adrenomyeloneuropathy. *Neurology* 83:2227–2231.
- Engelen, M., M. Barbier, I. M. Dijkstra, et al. 2014. X-linked adrenoleukodystrophy in women: a cross-sectional cohort study. *Brain* 137:693–706.
- Habekost, C. T., P. Schestatsky, V. F. Torres, et al. 2014. Neurological impairment among heterozygote women for X-linked Adrenoleukodystrophy: a case control study on a clinical, neurophysiological and biochemical characteristics. *Orphanet J. Rare Dis.* 9:6.
- van Geel, B. M., J. Assies, G. J. Weverling, and P. G. Barth. 1994. Predominance of the adrenomyeloneuropathy phenotype of X-linked adrenoleukodystrophy in The Netherlands: a survey of 30 kindreds. *Neurology* 44:2343–2346.
- Moser, H. W., A. B. Moser, S. Naidu, and A. Bergin. 1991. Clinical aspects of adrenoleukodystrophy and adrenomyeloneuropathy. *Dev. Neurosci.* 13:254–261.
- van Geel, B. M., J. Assies, R. J. Wanders, and P. G. Barth. 1997. X linked adrenoleukodystrophy: clinical presentation, diagnosis, and therapy. *J. Neurol. Neurosurg. Psychiatry* 63:4–14.
- Bezman, L., and H. W. Moser. 1998. Incidence of X-linked adrenoleukodystrophy and the relative frequency of its phenotypes. *Am. J. Med. Genet.* 76:415–419.
- Richards, S., N. Aziz, S. Bale, et al. 2015. Standards and guidelines for the interpretation of sequence variants: a joint consensus recommendation of the American College of Medical Genetics and Genomics and the Association for Molecular Pathology. *Genet. Med.* 17:405–424.
- Schule, R., T. Holland-Letz, S. Klimpe, et al. 2006. The Spastic Paraplegia Rating Scale (SPRS): a reliable and valid measure of disease severity. *Neurology* 67:430–434.
- Kurtzke, J. F. 1983. Rating neurologic impairment in multiple sclerosis: an expanded disability status scale (EDSS). *Neurology* 33:1444–1452.
- Horn, M. A., K. B. Nilsen, E. Jorum, S. I. Mellgren, and C. M. Tallaksen. 2014. Small nerve fiber involvement is frequent in X-linked adrenoleukodystrophy. *Neurology* 82:1678–1683.
- Miller, W. P., S. M. Rothman, D. Nascene, et al. 2011. Outcomes after allogeneic hematopoietic cell transplantation for childhood cerebral adrenoleukodystrophy: the largest single-institution cohort report. *Blood* 118:1971–1978.
- Finsterer, J., and R. Aliyev. 2015. Fasciculations in human hereditary disease. *Acta Neurol. Belg.* 115:91–95.
- Kemp, S., A. Pujol, H. R. Waterham, et al. 2001. *ABCD1* mutations and the X-linked adrenoleukodystrophy mutation database: role in diagnosis and clinical correlations. *Hum. Mutat.* 18:499–515.
- Raymond, G. V., R. Seidman, T. S. Monteith, et al. 2010. Head trauma can initiate the onset of adrenoleukodystrophy. *J. Neurol. Sci.* 290:70–74.
- Engelen, M., S. Kemp, and B. T. Poll-The. 2014. X-linked adrenoleukodystrophy: pathogenesis and treatment. *Curr. Neurol. Neurosci. Rep.* 14:486.